

中国结直肠癌肝转移诊断和综合治疗指南 (2023 版)

中国医师协会外科医师分会 中华医学会外科学分会胃肠外科学组 中华医学会外科学分会结直肠外科学组 中国抗癌协会大肠癌专业委员会 中国医师协会结直肠肿瘤专业委员会 中国临床肿瘤学会结直肠癌专家委员会 中国医师协会外科医师分会结直肠外科医师委员会 中国医师协会肛肠医师分会肿瘤转移委员会 中华医学会儿科学分会结直肠肿瘤学组 中国医疗保健国际交流促进会转移肿瘤治疗学分会 中国医疗保健国际交流促进会结直肠癌分会

通信作者:许剑民,Email:xujmin@aliyun.com

【摘要】 肝脏是结直肠癌血行转移最主要的靶器官,结直肠癌肝转移是结直肠癌治疗的重点和难点之一。为了提高我国结直肠癌肝转移的诊断和综合治疗水平,自 2008 年起各学组联合编写《中国结直肠癌肝转移诊断和综合治疗指南》并后续进行多次修订,以期指导对结直肠癌肝转移患者进行全面评估,精准地制定个体化的治疗目标,开展综合治疗,达到预防肝转移发生、提高肝转移灶局部毁损率、延长长期生存和改善生活质量的目的。此次修订后的《中国结直肠癌肝转移诊断和综合治疗指南(2023 版)》包括结直肠癌肝转移的诊断和随访、预防、多学科团队作用、手术及其他毁损治疗、可达到“无疾病证据”状态结直肠癌肝转移的新辅助和辅助治疗、无法达到“无疾病证据”状态结直肠癌肝转移的综合治疗等六部分,汇集总结国内外该领域的先进经验和最新成果,内容详尽,可操作性强。

【关键词】 结直肠肿瘤; 肝转移; 诊断; 综合治疗; 指南

Chinese guidelines for diagnosis and comprehensive treatment of colorectal liver metastases (2023 edition)

Chinese College of Surgeons; Chinese Society of Gastrointestinal Surgery; Chinese Society of Colorectal Surgery; The Committee of Colorectal Cancer CACA; Chinese Medical Association Colorectal Cancer Committee; Colorectal Cancer Expert Committee, Chinese Society of Clinical Oncology; Chinese Society of Colon and Rectal Surgeons; Chinese Society of Coloproctology Cancer Metastasis Committee; Chinese Society of Colorectal Oncology; Metastatic Tumor Therapeutics Branch, Colorectal Disease Branch, China International Exchange and Promotive Association for Medical and Health Care

Corresponding author: Xu Jianmin, Email: xujmin@aliyun.com

【Abstract】 The liver is the main target organ for hematogenous metastases of colorectal cancer, and colorectal liver metastasis is one of the most difficult and challenging situations in the treatment of colorectal cancer. In order to improve the diagnosis and comprehensive treatment in China, the Chinese guidelines for diagnosis and comprehensive treatment of colorectal liver metastases have been edited and revised for several times since 2008, with a view to guiding comprehensive evaluation of patients with colorectal liver metastases, accurately formulating personalized treatment goals and comprehensive treatments, so as to prevent the occurrence of liver metastases, increase the local damage rate of liver metastases, prolong long-term survival, and improve quality of life. The revised Chinese guidelines for diagnosis and comprehensive treatment of colorectal liver metastases

DOI: 10.3760/cma.j.cn115610-20221228-00762

收稿日期 2022-12-28

引用本文:中国医师协会外科医师分会,中华医学会外科学分会胃肠外科学组,中华医学会外科学分会结直肠外科学组,等.中国结直肠癌肝转移诊断和综合治疗指南(2023 版)[J].中华消化外科杂志,2023,22(1):1-28. DOI: 10.3760/cma.j.cn115610-20221228-00762.



(2023 edition) includes the diagnosis and follow-up, prevention, multidisciplinary team, surgery and other destructive treatment, neoadjuvant and adjuvant therapy for the "no disease evidence" state of colorectal liver metastases, comprehensive treatment for colorectal liver metastases which can not reach the "no disease evidence" state. The consensus collects and summarizes the advanced experience and latest achievements in this field at home and abroad, with detailed contents and strong operability.

【Key words】 Colorectal neoplasms; Liver metastases; Diagnosis; Comprehensive treatment; Guideline

第一部分 诊疗指南

肝脏是结直肠癌血行转移最主要的靶器官,结直肠癌肝转移(colorectal cancer liver metastases)是结直肠癌治疗的重点和难点之一^[1-2]。15%~25%结直肠癌患者在确诊时即合并有肝转移,而另15%~25%的患者将在结直肠癌原发灶根治术后发生肝转移,其中绝大多数(80%~90%)的肝转移灶初始无法获得根治性切除^[3-7]。肝转移也是结直肠癌患者最主要的死亡原因^[2],未经治疗的肝转移患者的中位生存期仅6.9个月,无法切除患者的5年生存率低于5%^[8-9],而肝转移灶能完全切除[或可以达到无疾病证据(no evidence of disease, NED)状态]患者的中位生存期为35个月,5年生存率可达30%~57%^[10-14]。有一部分最初肝转移灶无法根除的患者经治疗后可以转化为可切除或达到NED状态。因此,通过多学科团队(multidisciplinary team, MDT)对结直肠癌肝转移患者进行全面评估,个性化地制定治疗目标,开展相应的综合治疗,以预防结直肠癌肝转移的发生、提高肝转移灶手术切除率和5年生存率^[15-16]。

为提高我国结直肠癌肝转移的诊断和综合治疗水平,受卫生部临床重点学科项目资助(2008—2010年),中华医学会外科学分会胃肠外科学组和结直肠外科学组、中国抗癌协会大肠癌专业委员会自2008年起联合编写了《结直肠癌肝转移诊断和综合治疗指南》(草案),以指导我国结直肠癌肝转移的诊断和治疗,并于2010年、2013年先后进行2次修订。2016年、2018年、2020年联手中国医师协会外科医师分会结直肠外科医师委员会、中国医疗保健国际交流促进会结直肠癌肝转移治疗委员会、中国临床肿瘤学会结直肠癌专家委员会、中国医师协会结直肠肿瘤专业委员会、中国医师协会肛肠医师分会肿瘤转移委员会、中华医学会肿瘤学分会结直肠肿瘤学组、中国医师协会外科医师分会等多次共同修订了该指南。2022年再次一起总结国

内外先进经验和最新进展修订该指南。

《中国结直肠癌肝转移诊断和综合治疗指南(2023版)》以下简称本指南。对结直肠癌肝转移的诊断、预防、外科手术和其他综合治疗提出的建议,请各地医院根据实际情况予以应用。本文中出现的推荐级别、循证医学证据分类的界定,详见附录1。

一、结直肠癌肝转移的诊断与随访

(一)结直肠癌肝转移的定义

按照国际共识:同时性肝转移(synchronous liver metastases, SLM)是指结直肠癌确诊前或确诊时发现的肝转移;而结直肠癌根治术后发生的肝转移称为异时性肝转移(metachronous liver metastases, MLM)^[17]。本指南为便于诊疗策略的制订,将按照“结直肠癌确诊时合并肝转移”和“结直肠癌根治术后发生肝转移”两方面阐述。

(二)结直肠癌确诊时肝转移的诊断常规

对已确诊结直肠癌的患者,除血清CEA、CA19-9等肿瘤标志物检查、病理学分期评估外,应常规进行肝脏超声和腹部增强CT等影像学检查筛查及诊断肝脏转移瘤。对于超声或CT影像学检查高度怀疑但不能确诊的患者可加行血清AFP、肝脏超声造影和肝脏MRI平扫及增强检查^[18](**1a类证据, A级推荐**),肝脏细胞特异性造影剂增强MRI检查对于发现<1 cm的微小病灶准确率更高,有条件时可考虑。PET/CT检查不作为常规推荐,可在病情需要时酌情应用^[19-21](**2a类证据, B级推荐**)。

肝转移灶的经皮针刺活检仅限于病情需要时应用^[22]。

结直肠癌手术中必须常规探查肝脏以进一步排除肝转移可能^[23],对可疑的肝脏结节可行术中超声检查,必要时考虑同步切除或术中活检^[9](**3a类证据, B级推荐**)。

(三)结直肠癌根治术后肝转移的监测

结直肠癌根治术后,应对患者定期随访^[24-26],了解有无肝转移或其他远处转移的发生。

1. 每 3~6 个月进行 1 次病史询问、体格检查、肝脏超声检查和检测血清 CEA、CA19-9 等适当的肿瘤标志物,持续 2 年,以后每 6 个月 1 次至 5 年^[27](**1a 类证据, A 级推荐**),5 年后每年检查 1 次。

2. II 期和 III 期的结直肠癌患者,建议每年进行 1 次胸/腹/盆腔增强 CT 扫描,共 3~5 年^[28](**1b 类证据, A 级推荐**),以后每 1~2 年 1 次。对于超声或 CT 影像学检查高度怀疑肝转移瘤但不能确诊的患者应加行肝脏 MRI 等检查,并建议在随访过程中保持影像学检查方法的一致性。PET/CT 扫描不作常规推荐。

3. 术后 1 年内应进行电子结肠镜检查,若发现异常,需在 1 年内复查^[29-30];如无异常则推荐术后第 3 年复查,以后每 5 年 1 次。如果患者发病年龄<50 岁或确诊 Lynch 综合征则应适当增加电子结肠镜检查的频率。对于结直肠癌原发灶切除术前因梗阻等原因未完成全结肠镜检查的患者,应在术后 3~6 个月内完成首次电子结肠镜检查^[29-30](**1a 类证据, A 级推荐**)。

(四)结直肠癌肝转移灶达到 NED 后的随访

结直肠癌肝转移灶达到 NED 后,对患者也应进行密切随访,了解有无肝转移复发或出现其他远处转移的可能。

1. 建议术后 2 年内每 3 个月随访血清 CEA、CA19-9 和其他适当的肿瘤标志物,以后第 3~5 年内每 6 个月随访 1 次(**1a 类证据, A 级推荐**),5 年后每年 1 次。

2. 术后 2 年内每 3 个月进行 1 次腹/盆腔增强 CT 扫描或肝脏 MRI 增强检查,必要时肝脏细胞特异性造影剂增强 MRI 检查。以后每 6~12 个月进行 1 次,共 5 年^[28](**1a 类证据, A 级推荐**),5 年后每年 1 次。不推荐常规 PET/CT 扫描。

3. 其他随访内容和频次参照结直肠癌原发灶根治术后的随访进行。

(五)结直肠癌及其肝转移的相关基因检测

1. RAS 检测:推荐结直肠癌肝转移的患者均进行 KRAS 第 2、3、4 外显子以及 NRAS 第 2、3、4 外显子的检测^[31-33]。RAS 基因是否突变不仅具有预后意义^[34-36],更是预测抗 EGFR 治疗有效性的重要生物学标志物^[37-38](**1a 类证据, A 级推荐**)。其中 KRAS G12C 突变还有助于后线治疗对靶向药物的选择。

2. BRAF 检测:推荐结直肠癌肝转移患者进行 V600E 突变检测^[39-40],作为预后的评估指标^[41-43](**1b 类证据, A 级推荐**)以及疗效预测因子,以指导治疗

方案选择。

3. 错配修复基因(mismatch repair gene, MMR)/微卫星不稳定性(microsatellite instability, MSI)检测:推荐结直肠癌患者均进行检测^[44-46](**2b 类证据, B 级推荐**),以便更精准地制定治疗策略,尤其是对免疫检查点抑制剂的应用至关重要。采用 PCR+毛细管电泳法比较肿瘤组织与正常组织中微卫星序列长度的差异检测微卫星状态,是 MSI 检测的金标准^[47-48]。免疫组化检测 MMR 的蛋白表达(包括 MLH1、MSH2、MSH6 和 PMS2),因简便快捷已成为目前最常用的检测方式,可达到与 PCR 检测 90%~95% 以上的一致率^[49]。另外,有经过验证合格的二代测序法也可用于 MSI 检测。

4. UGT1A1 检测:UGT1A1 是伊立替康的药物代谢酶,其基因的多样性会显著影响该酶的活性。因此建议尽可能获取 UGT1A1 基因检测结果,据此慎重考虑伊立替康的给药剂量^[50-52](**2b 类证据, B 级推荐**)。

5. HER2 检测:在标准治疗失败的转移性结直肠癌患者中抗 HER2 治疗逐渐受到重视,建议转移性结直肠癌患者进行 HER2 检测^[53],为晚期患者后线治疗的临床决策提供依据(**2b 类证据, B 级推荐**)。

6. 其他:二代测序法检测肿瘤突变负荷^[54]、DNA 聚合酶 epsilon 和 delta 1 (POLE/POLD1)、神经营养因子受体酪氨酸激酶融合基因^[55]等,均可作为潜在的预测免疫检查点抑制剂治疗或靶向药物治疗疗效的生物标志物。

结直肠癌原发灶和肝转移灶的基因状态大多无差别^[56-58],对于无法获取肿瘤组织进行检测时可考虑液态活检技术(**2b 类证据, B 级推荐**)。

有研究发现基于循环肿瘤 DNA 指导的微小残留病灶(minimum residual disease, MRD)评估可有效提示结直肠癌患者接受治疗后的治愈情况,因此 MRD 有助于判断预后和制定下一步治疗策略,但目前仍存在诸多困难。

二、结直肠癌肝转移的预防

(一)结直肠癌原发灶根治性切除术

根治性手术切除结直肠癌病灶是迄今为止结直肠癌最有效的治愈方法^[59],也是预防肝转移发生的重要环节。

1. 结肠癌根治性手术范围包括肿瘤全部及其两端足够肠段和周围可能被浸润的组织和器官以及相关系膜、主要供应血管和淋巴引流区,具体

手术方式依照肿瘤部位不同而异,但均应遵循完整结肠系膜切除(complete mesocolic excision, CME)原则。

2. 直肠癌根治性手术范围应包括肿瘤全部及其两端足够肠段、周围可能被浸润的组织和器官以及相关的肠系膜和淋巴结。直肠中下段的肿瘤应遵循全直肠系膜切除(total mesorectal excision, TME)原则。

3. 术中发现存在切除范围外的可疑淋巴结,应进行术中活检或切除。

(二)结直肠癌确诊时无肝转移(及其他远处转移)的新辅助治疗

术前通过新辅助治疗杀灭未被影像学检查到的微小转移灶,可以最大程度地减少根治性手术后远处转移^[60-62]。

1. 中低位直肠癌的新辅助治疗(注:高位直肠癌,即肿瘤下缘距肛缘>12 cm,其新辅助治疗参照结肠癌。)

(1)联合放化疗或放疗。建议术前诊断为T3期及以上或任何T分期、淋巴结阳性的直肠癌,在不伴有明显出血、梗阻症状、无穿孔以及其他远处转移等情况时应用。包括长程联合放化疗和单纯短程放疗^[63-65]。

近年来,局部进展期直肠癌出现新治疗模式,全程新辅助治疗(total neoadjuvant treatment, TNT)^[66],将直肠癌术后辅助化疗提至术前,即术前进行新辅助化疗和同步放化疗,可获得更高的完全缓解率,有助于器官保留,还可以降低远处转移发生,改善长期生存^[67](**2a类证据, B级推荐**)。

(2)肝动脉和肿瘤区域动脉联合灌注化疗。对于术前分期为Ⅲ期,且不伴有出血、梗阻症状或无穿孔的患者,在有条件的单位可考虑应用。5-FU(或其前体药物)并可联合奥沙利铂,经肝动脉、肿瘤区域动脉分别灌注,化疗后7~10 d施行根治性切除术。目前的临床研究表明该方案虽不能明显降期,但对Ⅲ期结直肠癌患者有预防肝转移的作用^[68],建议在有条件的单位开展,不作为常规推荐。

2. 结肠癌的新辅助治疗

结肠癌的新辅助治疗尚无明确的循证医学证据,对于术前判断为Ⅲ期的患者可考虑肝动脉和肿瘤区域动脉联合灌注化疗,以减少肝转移的发生^[68],不作为常规推荐。

(三)无转移结直肠癌患者术中门静脉化疗、腹

腔化疗

对于该治疗方案的探讨目前已有令人鼓舞的数据^[69],如能联合术后辅助化疗,将可以减少肝转移的发生。但该结果仍需进一步临床研究证实,故不作为常规手段推荐,临床研究可关注。

(四)无转移结直肠癌患者根治术后的辅助治疗

1. 对于Ⅲ期结肠癌,术后辅助化疗能延长5年无病生存率及总生存率^[70],因此上述结肠癌患者在手术治疗后应进行3~6个月的辅助化疗,可选择的治疗方案有:FOLFOX、CapeOX、5-FU/LV或卡培他滨单药(**1a类证据, A级推荐**)。

pMMR/MSS/MSI-L的Ⅱ期患者如不存在复发转移高危因素(T4期、组织分化差、肿瘤周围淋巴管神经侵犯、肠梗阻或T3期伴有局部穿孔、切缘不确定或阳性、淋巴结活检数量<12枚),术后两药联合的辅助化疗在许多临床研究中获益不显著,故建议接受临床观察和随访^[71](**1b类证据, A级推荐**),或建议氟尿嘧啶单药治疗。但对于高危Ⅱ期患者应予以辅助化疗,方案参照Ⅲ期患者^[72-73](**2a类证据, B级推荐**)。

dMMR/MSI-H的Ⅱ期患者无论是否存在高危因素均可接受临床观察和随访,但T4期患者是否需辅助化疗目前尚有争议^[74]。

2. T3期及以上和任何T分期、淋巴结阳性的中低位直肠癌患者如术前没有进行放化疗,术后辅助化疗或放化疗能提高3年无病生存率及降低局部复发率^[75-76],但对于能否减少直肠癌肝转移方面研究有限,和辅助治疗的结合方式也需更多临床试验验证。术前接受放疗或联合放化疗的患者,术后也应接受辅助治疗,但尚无充分的循证医学证据。

总而言之,结直肠癌肝转移最有效的预防方式是规范化治疗结直肠癌。

三、MDT在结直肠癌肝转移诊治中的作用

对于肿瘤性疾病,MDT治疗模式是有效的手段^[77-78],因此建议结直肠癌肝转移的患者进入MDT治疗模式^[79](**1a类证据, A级推荐**)。结直肠癌的MDT以患者为中心,成员应包括结直肠外科、胃肠外科、肝外科、肿瘤内科、放疗科、放射介入科、放射和超声影像科、病理科及其他相关专业有一定资质的医师^[80]。MDT治疗模式可以减少个体医师做出的不完善决策^[81],其重要作用还包括:(1)更精确的疾病分期^[82];(2)减少治疗混乱和延误^[83-84];(3)更个性化的评估体系和治疗^[85];(4)更好的治疗衔

接^[86]; (5)更高的生活质量^[87]; (6)最佳的临床和生存获益^[88]; (7)最优的卫生经济学^[89-92]。

MDT 根据患者的体力状况、年龄、器官功能、合并症和肿瘤的分子病理特征等进行评估, 针对不同的治疗目标, 给予患者最合理的检查和最恰当的综合治疗方案^[80-93] (**1a 类证据, A 级推荐**)。

1. 患者全身状况较差, 不适合进行高强度治疗时, 建议单药(或联合靶向药物)减量的两药方案或最佳支持治疗, 以提高生活质量并尽量延长生存时间。如全身情况好转, 可以再进行高强度治疗。

2. 适合高强度治疗的患者, 应依据肝转移的具体情况 and 是否伴有其他转移等, 制定不同的治疗目标, 给予个体化的治疗方案。

(1) 肝转移灶初始即可以 R₀ 切除, 且手术难度不大、肿瘤生物学行为良好的患者, 其治疗目的是获得治愈^[94]。应该围绕手术治疗进行相应的新辅助和(或)辅助治疗, 以降低手术后复发风险。肝转移灶是否可以 R₀ 切除的判断应由肝外科、肿瘤外科、影像科专家联合进行。

肝转移灶可以 R₀ 切除, 但手术切除难度较大时也应积极联合其他肿瘤局部毁损手段[如 RFA 和(或)立体定向放疗等], 以达到 NED 状态^[95]。

(2) 肝转移初始无法切除, 但经过治疗有望转为 NED 状态, 且全身情况能够接受包括转移灶切除手术在内的局部治疗手段和高强度治疗患者。这类患者的治疗目的主要是最大程度缩小瘤体或增加剩余肝脏体积, 应采用最积极的综合治疗, 即转化治疗。

① 结直肠癌确诊时合并无法达到 NED 的肝转移

1) 结直肠癌原发灶存在出血、梗阻症状或穿孔时, 应先行切除结直肠癌原发病灶, 继而进行系统性化疗(或加用肝动脉灌注化疗), 并可联合应用分子靶向药物治疗 (**1b 类证据, A 级推荐**), 其中 dMMR/MSI-H 患者可选择免疫检查点抑制剂治疗。治疗后每 6~8 周进行肝脏超声和 CT 增强扫描检查并依据 RECIST 标准予以评估。临床重大决策时建议行 MRI 平扫及增强扫描检查。如果肝转移灶转变成可切除或有望达到 NED 状态时, 即予以手术治疗或手术联合其他肿瘤局部毁损手段; 如果肝转移灶仍不能达到 NED 状态, 则继续进行综合治疗。

2) 结直肠癌原发灶无出血、梗阻症状及无穿孔时可以行系统性化疗(或加用肝动脉灌注化疗), 并可联用分子靶向治疗 (**1c 类证据, B 级推荐**), 其中

dMMR/MSI-H 患者可选择免疫检查点抑制剂治疗。每 6~8 周评估 1 次, 如果转移灶转化成可切除或有望达到 NED 状态时, 即手术治疗(一期同步切除或分阶段切除原发病灶和肝转移灶)或手术联合其他肿瘤局部毁损手段; 如果肝转移灶仍不能达到 NED 状态, 则视具体情况手术切除结直肠癌原发病灶, 术后继续对肝转移灶进行综合治疗。此类患者也可选择先行切除结直肠癌原发病灶, 继而进一步治疗, 具体方案同上。

② 结直肠癌根治术后发生的无法达到 NED 状态的肝转移

1) 采用 5-FU/LV(或卡培他滨)联合奥沙利铂和(或)伊立替康的两药或三药方案作为一线化疗, 并可加用分子靶向治疗, 或联用肝动脉灌注化疗^[96] (**1b 类证据, A 级推荐**), 其中 dMMR/MSI-H 患者可选择免疫检查点抑制剂治疗^[97]。对氟尿嘧啶类药物不耐受的患者可考虑使用雷替曲塞 (**2b 类证据, B 级推荐**)。

2) 在肝转移发生前 12 个月内使用过奥沙利铂为基础的化疗作为辅助治疗的患者, 应采用 FOLFIRI 方案^[98]; 化疗结束后 >12 个月发生肝转移, 仍可采用 FOLFOX 或 CapeOX 化疗方案, 并可加用分子靶向药物治疗, 或联用肝动脉灌注化疗 (**3a 类证据, B 级推荐**), 其中 dMMR/MSI-H 患者可选择免疫检查点抑制剂治疗^[97]。

治疗后每 6~8 周检查肝脏超声、CT 增强扫描予以评估, 临床重大决策时建议行 MRI 平扫及增强扫描检查, 肝转移灶转为可切除或可以达到 NED 的患者, 即应接受肝转移灶切除手术或手术联合其他肿瘤局部毁损手段, 术后再予以辅助化疗; 如果肝转移灶仍不能达到 NED, 则应继续进行综合治疗。

(3) 还有一部分患者, 其肝转移灶可能始终无法切除或达到 NED 状态, 但全身情况允许接受较高强度的治疗。这类患者治疗目的为控制疾病进展, 应该采用较为积极的联合治疗。

对于结直肠癌原发灶无出血、梗阻症状及无穿孔时合并始终无法达到 NED 状态的肝转移灶患者是否应该切除原发灶目前仍有争议^[99]。因此, 需要 MDT 综合考虑肿瘤和患者情况, 进行个体化决策, 是否切除原发灶。

四、结直肠癌肝转移灶的手术及其他毁损治疗

(一) 手术治疗

手术完全切除肝转移灶仍是目前能治愈结直肠癌肝转移的最佳方法^[100-106], 故符合条件的患者

均应在适当的时候接受手术治疗。部分最初肝转移灶无法切除的患者经治疗后转化为可切除病灶时也应适时接受手术治疗。

1. 手术适应证和禁忌证

(1) 适应证:

手术切除的标准一直在演变,但主要应从以下 3 方面判断^[15,107](**2a 类证据, B 级推荐**):

① 结直肠癌原发灶能够或已经根治性切除;

② 根据肝脏解剖学基础和病灶范围,肝转移灶可完全(R_0)切除,且要求保留足够的功能性肝组织(剩余肝脏体积 $\geq 30\% \sim 40\%$,采用三维 CT、3D 数字成像技术等有助于评估剩余肝脏体积^[108-109]);

③ 患者全身状况允许,没有不可切除或毁损的肝外转移病变,或仅为肺部结节性病灶,但不影响肝转移灶切除决策的患者。

随着技术进步,肝转移灶的大小、数目、部位等已不再是影响判断结直肠癌肝转移患者是否适宜手术的单一决定因素。

另外,当前的文献资料已经将切缘 $< 1\text{ cm}$ ^[110-111]、可切除的肝门淋巴结转移^[112-114]、可切除的肝外转移病灶(包括肺、腹腔)^[114-118]等也纳入适宜手术切除的范畴(**4 类证据, C 级推荐**)。

(2) 禁忌证^[9,107,113](**3a 类证据, B 级推荐**):

① 结直肠癌原发灶不能取得根治性切除;

② 出现不适合局部处理的肝外转移;

③ 预计术后剩余肝脏体积不足;

④ 患者全身状况不能耐受手术。

2. 结直肠癌确诊时合并肝转移的手术治疗

(1) 结直肠癌原发灶和肝转移灶一期同步切除:

在肝转移灶小、且多位于周边或局限于半肝,肝切除量 $< 60\%$,肝门部淋巴结、腹腔或其他远处转移均可手术切除的患者可建议一期同步切除^[119-123]。有研究认为一期同步切除肝转移灶和原发结直肠癌病灶手术的并发症发生率和死亡率可能高于二期分阶段手术^[124-128],故患者的选择应较慎重,尤其是需要在两切口下完成的同步手术。

急诊手术由于缺少完备的术前检查资料和较高的感染发生概率,不推荐原发结直肠癌和肝脏转移病灶一期同步切除^[129](**2c 类证据, B 级推荐**)。

(2) 结直肠癌原发灶和肝转移灶二期分阶段切除:

术前评估不能满足一期同步切除条件的患者,可以先手术切除结直肠癌原发病灶,二期分阶段切除肝转移灶,时机选择在结直肠癌根治术后 4~

6 周;若在肝转移灶手术前进行系统性治疗,肝转移灶的切除可延至原发灶切除后 3 个月内进行。可根治复发性结直肠癌伴有可切除肝转移灶的治疗按结直肠癌确诊时合并肝转移处理,但倾向于进行二期分阶段切除肝转移灶。

先切除肝转移灶、再切除结直肠原发灶的“肝优先模式”(liver first approach)也已开展应用^[130-133],其手术的并发症发生率、死亡率和 5 年生存率均与传统模式的二期分阶段切除相同^[134-135](**3b 类证据, B 级推荐**)。

3. 结直肠癌根治术后发生肝转移的手术治疗

既往结直肠原发灶为根治性切除且不伴有原发灶复发,肝转移灶能完全切除且肝切除量 $< 70\%$ (无肝硬化者),应予以手术切除肝转移灶,也可考虑先行新辅助治疗(**3b 类证据, B 级推荐**)。

诊断结直肠癌根治术后发生肝转移应当有 > 2 项的影像学检查依据,包括肝脏超声、增强 CT 及 MRI 等检查,必要时可结合 PET/CT 扫描以确定病变范围和有无肝外转移,从而避免不必要的手术治疗^[136]。

4. 肝转移灶手术方式的选择^[137-140](**3b 类证据, B 级推荐**)

(1) 肝转移灶切除后至少保留 3 根肝静脉中的 1 根且剩余肝脏体积 $\geq 40\%$ (同时性肝切除)或 $\geq 30\%$ (异时性肝切除)。转移灶的手术切除应符合 R_0 原则,切缘至少 $> 1\text{ mm}$ ^[141-144]。

(2) 如是局限于左半肝或右半肝的较大肝转移灶且无肝硬化者,可行规则半肝切除术。

(3) 建议肝转移手术时采用术中超声或超声造影检查,有助于发现术前影像学检查未能诊断的肝转移病灶。

(4) 应用门静脉选择性栓塞或结扎可以使肝转移灶切除术后预期剩余肝脏代偿性增大,增加手术切除的可能。此方法被用于预计手术切除后剩余肝脏体积 $< 30\%$ 的肝转移患者。对于剩余肝脏体积为 $30\% \sim 40\%$,且接受强烈化疗而有肝实质损伤的患者,同样也可从中受益^[145-147](**4 类证据, C 级推荐**)。

放射性同时门静脉和肝静脉栓塞,又称肝静脉剥夺术^[148],对比联合肝脏离断和门静脉结扎的二步肝切除术(associating liver partition and portal vein ligation for staged hepatectomy, ALPPS)^[149],不仅可使剩余肝脏迅速增生,而且并发症发生率和死亡率低于 ALPPS^[150],具有操作简捷、创伤小、安全等优

点,但目前仍需更多研究进一步验证,临床研究可关注。

(5)ALPPS可使残留肝脏的体积在较短时间内明显增大而获得更多Ⅱ期肝切除的机会,但此手术复杂,并发症发生率及死亡率均高于传统肝切除术,故建议在严格选择的患者中由经验丰富的肝脏外科医师实施手术^[151-152]。

(6)肝移植对于经过肝切除、局部消融治疗、系统性化疗、介入治疗、分子靶向治疗、免疫检查点抑制剂治疗等多种方法的联合或序贯治疗仍无法达到NED状态但仍局限于肝转移的患者,可酌情谨慎选择肝移植^[153-154]。

5. 肝转移灶切除术后复发和肝外转移灶的切除

在全身状况和肝脏条件允许的情况下,对于可切除肝转移灶术后复发病灶,经MDT讨论后,可再次选择手术切除或其他局部治疗,文献报道显示其手术并发症发生率和死亡率并不高于第一次肝转移灶切除术,而且可获得相同的术后生存率^[155-157](**3b类证据,B级推荐**)。

同样,在患者全身状况允许时,如果肺^[157]和腹腔^[158-159]等肝外转移病灶可完全切除,也应进行同步或分阶段切除(**3b类证据,B级推荐**)。

(二)可以达到NED状态的肿瘤局部毁损治疗

除手术切除肝转移灶外,有些治疗手段(如RFA、微波消融和放射治疗)也能使病灶发生彻底毁损,所以对于手术切除难度较大的个别肝转移灶应积极联合此类手段,以使更多患者有机会达到NED状态,提高5年生存率。

五、可达到NED状态结直肠癌肝转移的新辅助治疗及辅助治疗

(一)新辅助治疗

对可达到NED状态的结直肠癌肝转移患者可考虑进行新辅助治疗,主要基于以下几方面原因:

(1)新辅助化疗提供“窗口期”,观察有无新出现的无法切除转移灶,减少没有必要的手术^[160]。

(2)新辅助治疗可增加R₀手术的机会,增加术后剩余肝脏体积^[161-162]。

(3)新辅助化疗可作为评价化疗方案敏感性的依据,指导术后化疗方案选择^[163-167]。

(4)新辅助化疗的疗效,可作为患者预后评估指标^[163,168]。

(5)新辅助化疗结合辅助化疗,可能改善接受治愈性手术患者的预后^[169-170]。

新辅助治疗在应用时也应关注如下情况的发生:

(1)化疗可能会造成肝脏损伤:如与奥沙利铂治疗相关的肝窦阻塞综合征^[171-177];与伊立替康治疗相关的脂肪变性和脂肪性肝炎等^[178-180]。这些损害均可能增加肝切除术后并发症^[181-182]。

(2)影像学检查消失的转移灶术中仍应积极探查^[183-185],例如术中超声造影等^[186],若病灶有残存,应积极切除;若病灶消失而无法精确定位者应慎重考虑是否切除^[162,187]。

(3)转移灶进展致使无法达到NED状态。

1. 结直肠癌确诊时合并肝转移的新辅助治疗

在原发灶无出血、梗阻症状或穿孔时,除肝转移灶在技术上切除容易且不存在不良预后因素的患者[如临床危险评分(clinical risk score, CRS)<3]外,可考虑应用新辅助治疗^[15,188-190](**2a类证据,B级推荐**),尤其是肝转移灶体积较大、转移灶数量较多或存在原发灶淋巴结可疑转移的患者。

系统性化疗的方案包括FOLFOX、FOLFIRI、CapeOX或FOLFOXIRI^[191-194],可否联合分子靶向治疗目前仍有争议,同时也可以考虑联合肝动脉灌注化疗^[195-197]。

为减少化疗对肝脏手术的不利影响,新辅助化疗原则上≤6个周期^[72,198](**1a证据,A级推荐**),一般建议2~3个月内完成并进行手术^[199-200]。

2. 结直肠癌根治术后发生肝转移的新辅助治疗

原发灶切除术后未接受过化疗的患者,或者发现肝转移12个月前已完成化疗的患者,可采用新辅助治疗(方法同上),时间2~3个月^[198,201](**2a类证据,B级推荐**)。而肝转移发现前12个月内接受过化疗的患者,一般认为新辅助化疗作用有限,宜直接切除肝转移灶,继而术后辅助治疗^[188](**2a类证据,B级推荐**)。也可考虑更换化疗方案进行新辅助化疗^[184,197],或术前联合肝动脉灌注化疗^[195]。

(二)肝转移灶切除术后的辅助治疗

建议肝转移灶完全切除的患者接受术后辅助化疗^[202-204],特别是没有进行过术前化疗及辅助化疗的患者,推荐手术前后的化疗时间总长≤6个月(**2c类证据,B级推荐**)。对于术前接受过肝动脉灌注化疗且有效的患者,术后也可考虑同时联合肝动脉灌注化疗^[205-208]。经过术前化疗(包括联合分子靶向药物)证实有效的方案,术后如无禁忌证应该作为首选的辅助治疗方案。

六、无法达到 NED 状态结直肠癌肝转移的综合治疗

对于无法达到 NED 状态的结直肠癌肝转移的综合治疗包括系统性化疗和介入化疗、分子靶向治疗、免疫检查点抑制剂治疗以及针对肝脏病灶的局部治疗如消融治疗、无水酒精注射、放射治疗等,治疗方案选择应基于对患者治疗前的精确评估。

部分初诊无法达到 NED 状态的肝转移患者,经过系统综合治疗后,即转化治疗,可转为适宜手术切除^[209-210]或达到 NED 状态。其术后 5 年生存率与初始肝转移灶手术切除的患者相似^[211-212],此类患者应当采取较为积极的诱导方案,应用有效的强烈化疗,并考虑联合肝动脉灌注化疗及分子靶向药物治疗。

对于肝转移灶始终无法达到 NED 状态的患者,综合治疗也可明显延长中位生存期,控制疾病快速进展,明显改善生存质量^[213-216]。因此,积极的综合治疗对于适合强烈治疗的晚期结直肠癌肝转移患者同样意义重大。

(一) 系统性化疗和肝动脉灌注化疗

化疗开始前应充分评估患者的身体状况和肿瘤分期,事先规划好患者的后续治疗和预计有严重化疗毒性反应时剂量和方案的调整。开始治疗时必须考虑患者的分类(详见“MDT 在结直肠癌肝转移诊治中的作用”节)化疗的安全性以及将来手术和(或)局部病灶毁损治疗的可能性。

1. 初始化疗

(1) 对于肝转移灶有潜在 NED 状态可能的患者进行转化治疗至关重要。转移灶出现的早期退缩(early tumor shrinkage, ETS)更是预后的重要指标之一^[217-219]。

对于 pMMR/MSS/MSI-L 的患者,5-FU/LV(或卡培他滨)联合奥沙利铂和(或)伊立替康的化疗方案具有较高的转化切除率(1b 类证据, A 级推荐),应该作为首选化疗方案。化疗联合分子靶向药物可以进一步提高转化率^[220-222](1b 类证据, A 级推荐)。现有的研究数据显示,化疗联合贝伐珠单抗抗体有良好的疾病控制率和转化切除率^[223],而 RAS 野生型患者还可以采用化疗联合西妥昔单抗抗体治疗^[224-225](1b 类证据, A 级推荐)。

对于 dMMR/MSI-H 的患者,相较于化疗±靶向治疗,帕博利珠单抗抗体免疫检查点抑制剂治疗可明显提高疾病控制率和转化切除率^[226-227],可以作为首选。

BRAF 的状态是重要的预后指标, BRAF V600E 突变的结直肠癌肝转移患者大多预后较差,有数据提示对该类患者化疗联合抗 EGFR 治疗的获益比较有限^[228]。因此对 BRAF V600E 突变的结直肠癌肝转移患者,初始治疗采用化疗联合抗 VEGF 单抗抗体也是值得考虑的选择。

有数据提示,对于 RAS 野生型的结直肠癌肝转移患者,抗 EGFR 治疗的疗效与肿瘤部位存在相关性^[210, 224, 229]。原发灶位于左半结肠(脾曲至直肠)肝转移患者使用抗 EGFR 单抗抗体在客观缓解率和总生存上优于抗 VEGF 单抗抗体,而原发灶位于右半结肠(回盲部至脾曲)肝转移患者,抗 EGFR 单抗抗体在客观反应率上优于抗 VEGF 单抗抗体,但总体生存不如抗 VEGF 单抗抗体。

以 FOLFOXIRI 为代表的三药化疗方案也有较高的切除转化率^[230-232],在分子靶向药物无法使用且综合患者年龄、体能状况及肝功能状态等因素均适宜的情况下应该作为首选,但该方案的不良反应较多,应予以关注。目前三药化疗方案联合贝伐珠单抗抗体的研究有较好的临床数据^[232-235],可在选择性的患者中谨慎应用^[214, 231, 234](2b 类证据, B 级推荐)。还有研究发现三药化疗联合抗 EGFR 单抗抗体比单纯三药化疗有更高的客观缓解率,能潜在提高 R₀ 切除率,改善总体生存^[229-230](2b 类证据, B 级推荐)。

(2) 对于肝转移灶始终无法达到 NED 状态的患者,5-FU/LV(或卡培他滨)联合奥沙利铂或伊立替康的化疗方案是首选,也可以联合分子靶向药物治疗^[160, 203, 214](2b 类证据, B 级推荐)。含奥沙利铂和伊立替康的三药化疗尽管有较高的反应率,但毒性也较大,是否应在此类患者中应用尚不明确。

2. 诱导化疗后病情缓解或稳定,但肝转移灶仍无法 R₀ 切除时可考虑进入维持治疗(如采用毒性较低的 5-FU/LV 或卡培他滨单药,均可联合贝伐珠单抗抗体)^[236-240]或单独使用贝伐珠单抗抗体^[241]或暂停化疗,以降低持续高强度联合化疗的不良反应^[241-242]。

3. 初始化疗病情进展后的化疗选择

(1) FOLFOX(或 CapeOX)方案±分子靶向治疗,如果病情进展后可以考虑改用 FOLFIRI(或 Mxeliri^[243])方案; FOLFIRI 方案±分子靶向治疗,如果病情进展可考虑改用 FOLFOX(或 CapeOX)方案,仍可考虑与分子靶向药物联合^[244-246]。如果病情第二次进展,可以使用瑞戈非尼^[247]或呋喹替尼^[248]或西妥昔

单克隆抗体^[249-250](未用过此类药者,仅限RAS野生型,可联合伊立替康)或曲氟尿苷替匹嘧啶(TAS-102)±贝伐珠单抗^[251-252]或最佳支持治疗^[62](**2a类证据,B级推荐**)。

(2)5-FU/LV联合分子靶向治疗后如果病情进展,应改用FOLFOX、FOLFIRI或CapeOX(均可联合分子靶向治疗),病情再次进展时推荐瑞戈非尼或呋喹替尼或曲氟尿苷替匹嘧啶(TAS-102)或进行最佳支持治疗^[253](**3b类证据,B级推荐**)。

(3)已有研究表明对于dMMR/MSI-H的结直肠癌肝转移患者,免疫检查点抑制剂用于二线及三线治疗显示出令人鼓舞的效果^[254-257]。对于未使用过该类治疗的dMMR/MSI-H患者可以优先选择免疫检查点抑制剂。

(4)对于三线失败后的治疗目前尚无标准方案。据文献报道联合抗BRAF V600E(伊立替康+抗EGFR+BRAF抑制剂,或抗EGFR+BRAF抑制剂±MEK抑制剂)的治疗方案^[39-40, 258-261]、抗HER2治疗(HER2阳性患者)^[262-264]都能起到一定作用,但考虑到上述药物的适应证和可及性问题,仅建议在临床研究中谨慎使用,不作常规推荐。

4. 对于肝转移为主肿瘤负荷较大且药物治疗效果不明显的患者,或者难治性患者,或者不能耐受系统治疗的患者,可在适当时机联合应用肝动脉灌注化疗、TACE,有助于延长疾病无进展时间和总体生存期^[265-267],尤其是药物洗脱微球动脉化疗栓塞,可以进一步提高疗效^[268-269]。但是单独应用上述治疗并不比全身化疗更具优势^[270-271]。

(二)局部毁损治疗

对于无法手术切除的肝转移灶,应根据其位置、治疗目标、治疗相关并发症及患者自身情况,在系统性化疗基础上选择适当的局部毁损工具(如射频消融、微波消融、冷冻治疗、放射治疗等)以加强局部病灶控制,具体应由MDT进行决策并结合患者意愿。

1. 消融治疗

(1)射频消融

射频消融术使用方便,安全性好^[272-274],且能高效破坏肝转移灶的肿瘤细胞。对于始终无法达到NED状态的晚期结直肠癌肝转移患者,现有资料表明单独使用射频消融治疗肝转移的生存率仅略高于

其他非手术治疗^[275-278],目前仅作为化疗无效后的治疗选择或肝转移灶术后复发的治疗。建议应用时选择肝转移灶最大直径<3 cm^[279]且一次消融最多5枚^[15]。

对于预期术后剩余肝脏体积过小时,可先切除部分较大的肝转移灶,对剩余直径<3 cm的转移病灶进行射频消融。或对于一般情况不适宜或不愿意接受手术治疗的不可切除结直肠癌肝转移患者也可以考虑射频消融治疗,但应注意避免肝外热损伤^[280-281]、针道转移、感染和消融不彻底等问题。

(2)微波消融

微波的传导不受组织干燥碳化限制,使肿瘤内部在较短时间内就可产生较高温度和更大消融带,而使肿瘤细胞坏死更彻底^[282]。与单纯化疗相比,结合微波消融治疗经过选择的不可切除结直肠癌肝转移患者可以更有效地提高生存率^[283-285]。

(3)冷冻治疗

尽管冷冻治疗严格挑选不可切除结直肠癌肝转移患者在一定程度上提高生存率^[286-288],但是较高的局部复发率和并发症发生率(可达35%,包括ARDS和DIC等^[289])限制了该技术的广泛应用。

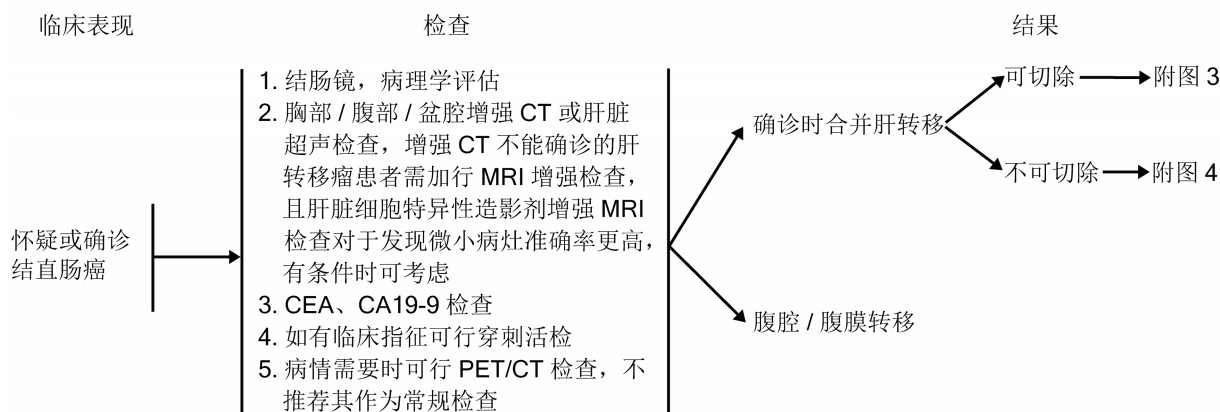
2. 放射治疗

对于直径≤3 cm的肝脏寡转移灶,立体定向放射治疗(stereotatic body radiation therapy, SBRT)可以取得较好的局部控制率。SBRT是一种精确的外放疗技术,采用单次高剂量(5~30 Gy)大分割(1~5次)照射,以取得类似外科手术的效果,又称之为立体定向消融放疗(stereotatic radiotherapy, SABR)。生物等效剂量(biological equivalent dose, BED)与肿瘤控制率正相关,BED≥100 Gy有更高的局部控制率。SABR安全性较高,常见不良反应为肝功能异常^[290-292]及胃肠道反应。Child-Pugh评分、胃肠道疾病史、全身治疗和肿瘤位置等需在实施SABR前评估。放射治疗计划设计时应避免危及胃肠、脊髓等器官的高剂量照射。

(三)其他治疗方法

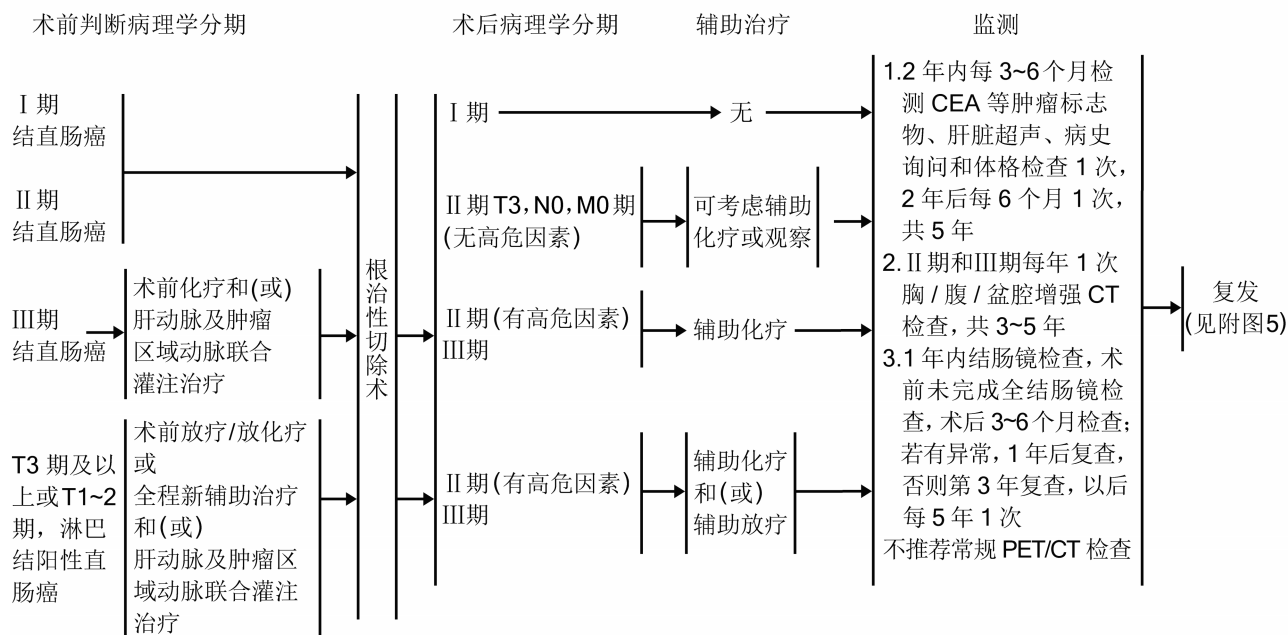
其他治疗方法包括选择性内放射(selective internal radiotherapy, SIRT)、无水酒精瘤内注射^[293]、局部放射性粒子植入和中医中药治疗等,可作为综合治疗的一部分,单独使用可能会失去其治疗意义。

第二部分 诊疗流程



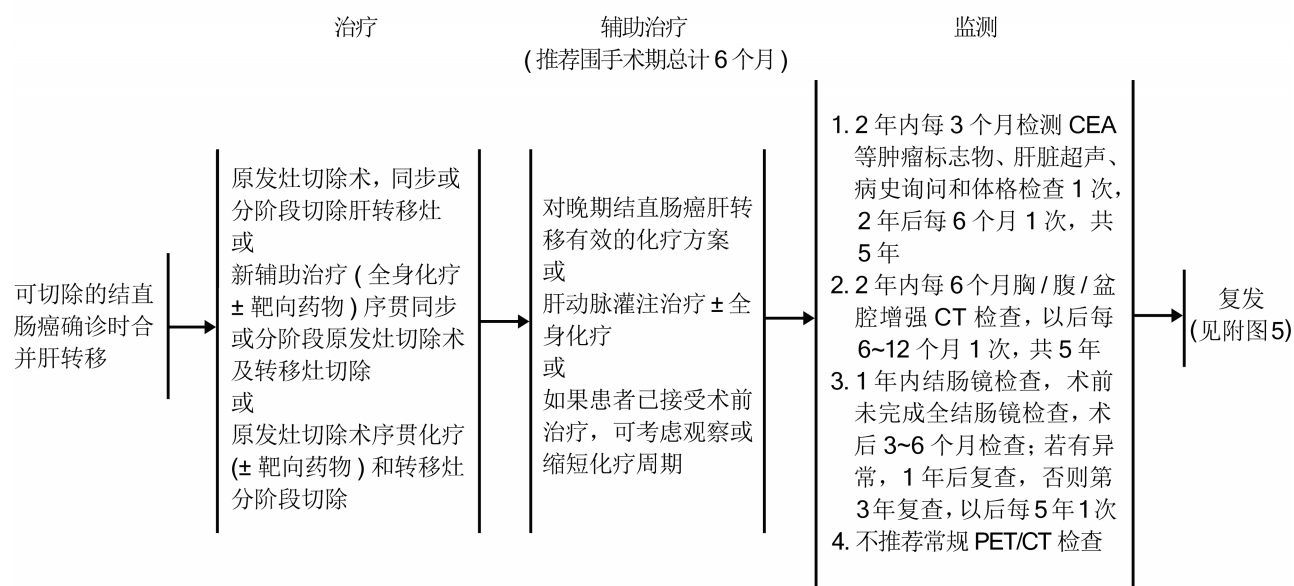
附图 1 结直肠癌确诊时肝转移的诊断

Figure 1 Diagnosis of liver metastasis at the time of diagnosis of colorectal cancer



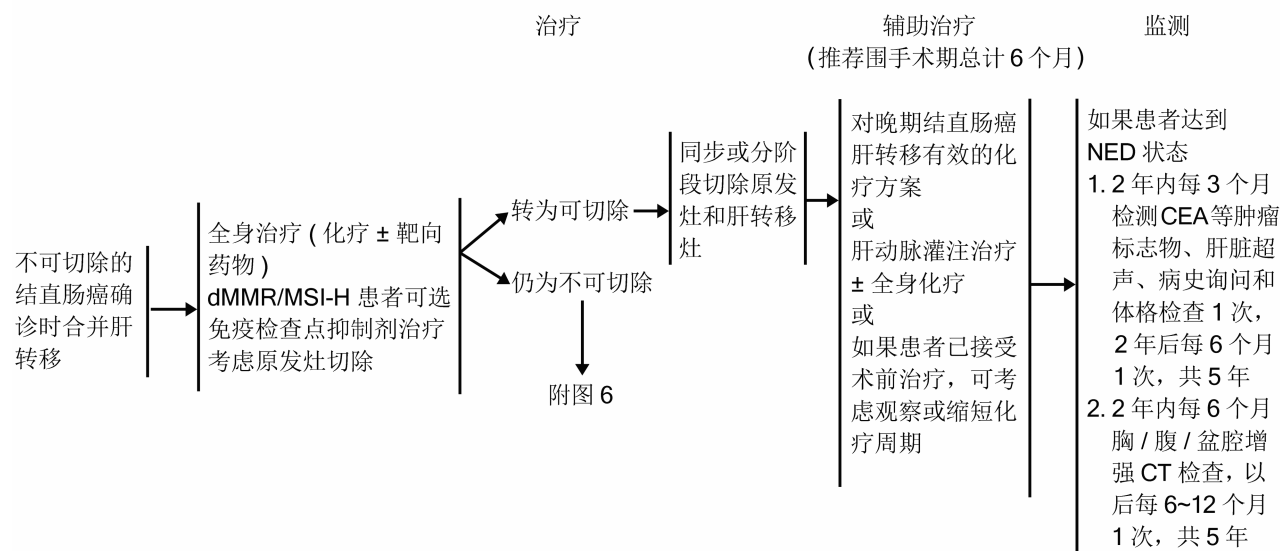
附图 2 结直肠癌肝转移的预防

Figure 2 Prevention of colorectal cancer liver metastases



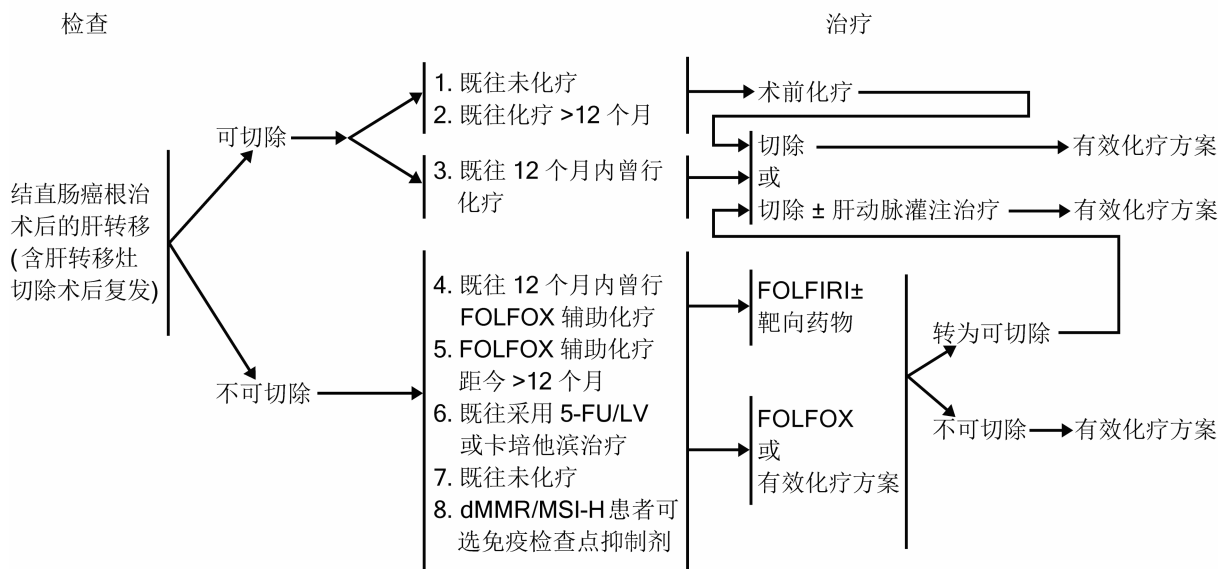
附图 3 结直肠癌确诊时合并肝转移的治疗 (转移灶可切除)

Figure 3 Treatment of liver metastases at diagnosis of colorectal cancer (resectable metastatic lesions)



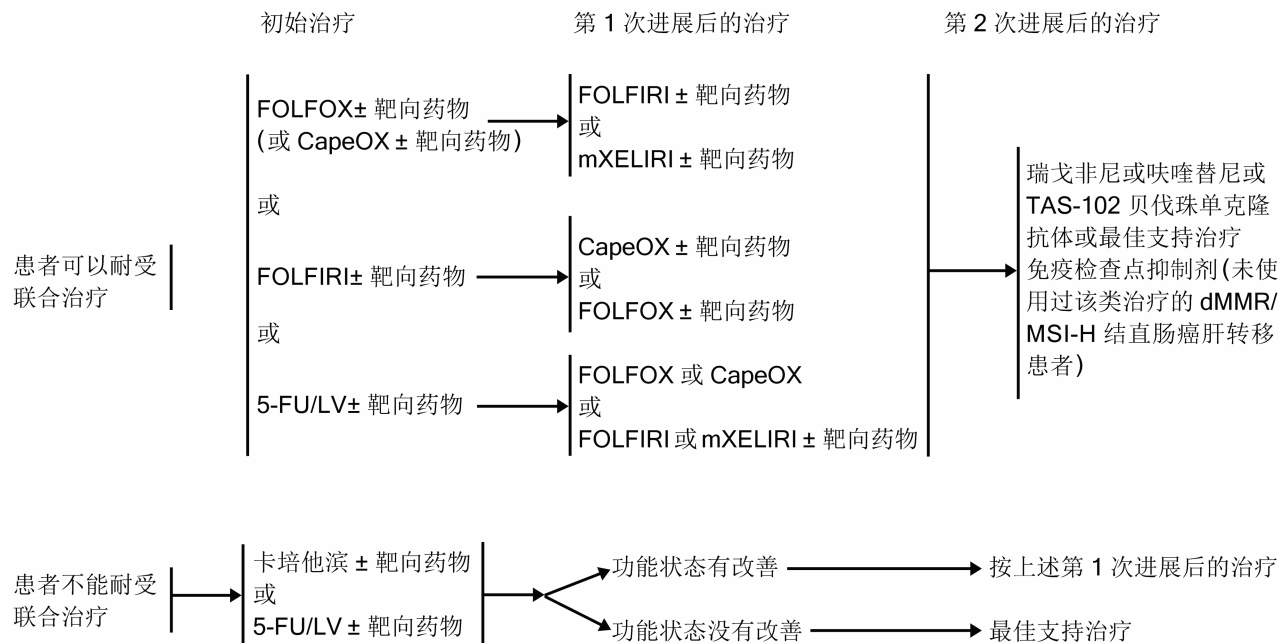
附图 4 结直肠癌确诊时合并肝转移的治疗 (转移灶不能切除)

Figure 4 Treatment of liver metastases at diagnosis of colorectal cancer (non-resectable metastatic lesions)



附图 5 结直肠癌根治术后的肝转移的治疗

Figure 5 Treatment of liver metastases after radical resection of colorectal cancer



附图 6 不可切除结直肠癌肝转移的治疗

Figure 6 Treatment of non-resectable colorectal cancer liver metastases

附录 1 推荐级别的分类

推荐分级	证据水平	证 据
A	1a	RCTs 的系统综述
	1b	单项 RCT(95% 可信区间较窄)
	1c	全或无, 必须满足以下要求 (1)传统方法治疗全部致残或治疗失败, 新方法治疗后, 有部分患者存活或治愈 (2)传统方法治疗许多患者死亡或治疗失败, 新方法治疗后, 无一死亡或治疗失败
B	2a	队列研究的系统综述
	2b	单项队列研究(包括质量较差的 RCT) (如随访率<80%)
	2c	结局研究
	3a	病例对照研究的系统综述
	3b	单项病例对照研究
C	4	系列病例分析及质量较差的病例对照研究
D	5	没有分析评价的专家意见

注: RCT 为随机对照研究

附录 2 结直肠癌分期

美国癌症联合委员会(AJCC)结直肠癌 TNM 分期系统(第八版, 2017 年)

原发肿瘤(T)

- T_x 原发肿瘤无法评估
 T₀ 无原发肿瘤
 T_{is} 原位癌: 黏膜内癌(侵犯黏膜固有层)
 T₁ 肿瘤侵犯黏膜下层
 T₂ 肿瘤侵犯固有肌层
 T₃ 肿瘤穿透固有肌层抵达浆膜下, 或侵犯无腹膜覆盖的结直肠旁组织
 T_{4a} 肿瘤穿透至脏层腹膜(包括肿瘤所致肠道严重穿孔/肿瘤经炎症区域持续浸润到达脏层腹膜表面)
 T_{4b} 肿瘤与邻近器官/组织结构粘连, 或直接侵犯其他器官/组织

区域淋巴结(N)

- N_x 区域淋巴结无法评估
 N₀ 区域淋巴结无转移
 N₁ 1~3枚区域淋巴结转移(淋巴结中的肿瘤≥0.2 mm), 或存在癌结节而淋巴结阴性
 N_{1a} 1枚区域淋巴结转移
 N_{1b} 2~3枚区域淋巴结转移
 N_{1c} 无区域淋巴结转移, 但肿瘤在浆膜下、肠系膜或无腹膜覆盖的结直肠旁或直肠系膜组织中种植
 N₂ 4枚或4枚以上区域淋巴结转移
 N_{2a} 4~6枚区域淋巴结转移
 N_{2b} 7枚或更多的区域淋巴结转移

远处转移(M)

- M₀ 无远处转移
 M₁ 有远处转移

- M_{1a} 转移局限在单个器官或部位(如: 肝脏、肺、卵巢, 非区域淋巴结转移), 无腹膜转移
 M_{1b} 转移超过一个器官/部位, 无腹膜转移
 M_{1c} 转移至腹膜表面, 伴/不伴其他器官/部位转移

分期分组

分期	T	N	M	Dukes 分期	MAC
0	T _{is}	N ₀	M ₀	—	—
I	T ₁	N ₀	M ₀	A	A
	T ₂	N ₀	M ₀	A	B1
II A	T ₃	N ₀	M ₀	B	B2
II B	T _{4a}	N ₀	M ₀	B	B2
II C	T _{4b}	N ₀	M ₀	B	B3
	T ₁ ~T ₂	N ₁ /N _{1c}	M ₀	C	C1
III A	T ₁	N _{2a}	M ₀	C	C1
	T ₃ ~T _{4a}	N ₁ /N _{1c}	M ₀	C	C2
	T ₂ ~T ₃	N _{2a}	M ₀	C	C1/C2
III B	T ₁ ~T ₂	N _{2b}	M ₀	C	C1
	T _{4a}	N _{2a}	M ₀	C	C2
	T ₃ ~T _{4a}	N _{2b}	M ₀	C	C2
IV A	任何 T	任何 N	M _{1a}	—	—
IV B	任何 T	任何 N	M _{1b}	—	—
IV C	任何 T	任何 N	M _{1c}	—	—

组织学分级(G)

- G_x 分化程度不能被评估
 G₁ 高度分化
 G₂ 中度分化
 G₃ 低度分化
 G₄ 未分化

附录 3 临床危险评分(CRS)

包括以下 5 项参数, 每符合 1 项计 1 分(0~2 分为 CRS 低评分, 3~5 分为 CRS 高评分):

- (1)原发肿瘤淋巴结阳性
- (2)同时性肝转移或原发灶切除后无病生存时间<12个月
- (3)肝转移肿瘤数目>1个
- (4)术前 CEA>200 ng/mL
- (5)转移肿瘤最大径>5 cm

附录 4 分子靶向药物简介

在无法达到 NED 状态的结直肠癌肝转移治疗中应用分子靶向药物已被证实安全有效^[294-296], 但目前的研究资料不建议多种靶向药物联合应用^[297-300]。目前中国大陆范围内批准使用的分子靶向药物如下:

1. 西妥昔单抗克隆抗体

西妥昔单抗克隆抗体为人鼠嵌合型的 EGFR 单克隆抗体, 单用或联合化疗治疗结直肠癌肝转移均有良好的临床效果^[301-305]。但是西妥昔单抗克隆抗体只对 RAS 基因野生型患者治疗有较好的效果, 而在 RAS 基因突变型患者中应用并不提高疗效^[306-308]。BRAF 突变的患者获益有限, 这可能与疾

病的不良预后有关^[304,309-312]。

目前认为可以同西妥昔单抗联合的化疗方案包括 FOLFOX 和 FOLFIRI^[229,301,313], 不建议其与 CapeOX 或 5-FU 推注方案联用^[312], 且对于西妥昔单抗联合的跨线治疗是否有效仍存在争议^[314]。约有 3% 的患者会在西妥昔单抗联合的给药过程中出现严重的输液反应, 包括过敏反应, 应引起足够的重视。

★含西妥昔单抗联合的方案

西妥昔单抗联合首次剂量 400 mg/m² 输注, 输注时间为 120 min; 然后每周 250 mg/m², 输注时间为 120 min, +FOLFOXIRI 或 FOLFIRI 或 FOLFOX。

西妥昔单抗联合首次剂量 400 mg/m² 输注, 输注时间为 120 min; 然后每 2 周 500 mg/m², 输注时间为 120 min, +FOLFOXIRI 或 FOLFIRI 或 FOLFOX。

2. 贝伐珠单抗联合

贝伐珠单抗联合为人源化的 VEGF 单抗联合, 联合化疗作为不可切除的结直肠癌肝转移一线治疗有良好的效果^[315-318]。同样, 贝伐珠单抗联合在肿瘤进展后的二线治疗上疗效也得到了证实^[318-322] (**3b 类证据, B 级推荐**)。但贝伐珠单抗联合易引起出血和伤口延迟愈合, 如在其治疗后需进行手术, 建议手术时机选择在最后一次贝伐珠单抗联合使用后的 6~8 周^[192,323-325]。

★含贝伐珠单抗联合的方案

贝伐珠单抗联合 5 mg/kg 静脉滴注, 每 2 周重复, +5-FU 或 FOLFOX 或 FOLFIRI 或 FOLFOXIRI

贝伐珠单抗联合 7.5 mg/kg 静脉滴注, 每 3 周重复, +CapeOX

3. 瑞戈非尼

瑞戈非尼是一种口服多靶点酪氨酸激酶抑制剂, 可以阻断数个促血管生成的血管内皮生长因子受体 (vascular endothelial growth factor, VEGFR) 抑制与肿瘤生成和肿瘤微环境相关的多种激酶的活性。新近的临床研究表明: 对于 RAS 野生型的转移性结直肠癌患者在初始化疗进展后应用瑞戈非尼序贯二线化疗联合分子靶向药物治疗有更好的生存获益^[326], 但仍需更多的临床研究证实。瑞戈非尼大部分的不良反应发生在治疗的早期阶段, 主要包括手足皮肤反应、疲乏、腹泻、高血压、皮疹等, 均可预测且可通过暂停给药、剂量下调及对症处理后缓解。

目前, 瑞戈非尼已获批用于治疗之前接受过氟尿嘧啶、奥沙利铂和伊立替康为基础的化疗, 以及既往接受过抗 VEGF 治疗, 抗 EGFR 治疗 (RAS 野生型) 的转移性结直肠癌患者^[247,327]。

★瑞戈非尼用法

瑞戈非尼 160 mg 口服, 每日 1 次, 第 1~21 天, 每 28 d 重复

4. 呋喹替尼

呋喹替尼也是一种口服酪氨酸激酶抑制剂, 高度选择性抑制 VEGFR1、2 和 3 三种亚型。呋喹替尼可抑制 VEGFR 磷酸化, 从而抑制肿瘤血管生成, 最终抑制肿瘤生长。全国多中心 FRESKO 研究发现对于二线或以上标准化疗失败的转移性结直肠癌患者, 呋喹替尼单药治疗显著延长生存,

且安全性良好, 不良反应可控^[248]。呋喹替尼常见的严重不良反应为高血压、手足综合征和蛋白尿等。

目前呋喹替尼已获批用于既往接受过氟尿嘧啶、奥沙利铂和伊立替康为基础的化疗, 以及无论既往是否接受过抗 VEGF 治疗或抗 EGFR 治疗 (RAS 野生型) 的转移性结直肠癌患者。

★呋喹替尼用法

呋喹替尼 5 mg 口服, 每日 1 次, 第 1~21 天, 每 28 d 重复

附录 5 化疗方案

★5-FU/LV

LV 500 mg/m² 静脉滴注 2 h, 每周 1 次×6

5-FU 500 mg/m² 在 LV 滴注开始 1 h 后静脉推注, 每周 1 次×6, 每 8 周重复

5-FU 370~400 mg/m²+LV 400 mg/m² 每日 1 次×5, 每 4 周重复

★卡培他滨

卡培他滨 1 250 mg/m² 每日 2 次口服, 第 1~14 天, 每 3 周重复

★FOLFOX

☆mFOLFOX6

奥沙利铂 85 mg/m² 静脉滴注 2 h, 第 1 天

LV 400 mg/m² 静脉滴注 2 h, 第 1 天

5-FU 400 mg/m² 静脉推注, 第 1 天, 然后 1 200 mg/(m²·d)×2 持续静脉输注 (总量 2 400 mg/m², 输注 46~48 h)

每 2 周重复

★CapeOX

奥沙利铂 130 mg/m², 第 1 天

卡培他滨 850~1 000 mg/m², 每日 2 次, 持续 14 d

每 3 周重复

★FOLFIRI

伊立替康 180 mg/m² 静脉滴注 30~120 min, 第 1 天

LV 400 mg/m² 与伊立替康同时输注, 持续时间相同, 第 1 天

5-FU 400 mg/m² 静脉推注, 第 1 天, 然后 1 200 mg/m²/d×2 持续静脉输注 (总量 2 400 mg/m², 输注 46~48 h)

每 2 周重复

★mXELIRI

伊立替康 200 mg/m², 第 1 天

卡培他滨 800 mg/m², 每日 2 次, 持续 14 d

每 3 周重复

★FOLFOXIRI

伊立替康 150 mg/m², 奥沙利铂 85 mg/m², LV 400 mg/m² 静脉滴注, 第 1 天

5-FU 2 400 mg/m² 48 h 持续滴注, 第 1 天开始

每 2 周重复

★曲氟尿苷替匹嘧啶 (TAS-102)

曲氟尿苷替匹嘧啶 (TAS-102) 35 mg/m² (单次≤80 mg) 口服, 每日 2 次, 第 1~5 天和第 8~12 天, 每 28 d 重复

曲氟尿苷替匹嘧啶 (TAS-102) 是一种新型口服核苷类

复方制剂,其中曲氟尿苷干扰癌细胞 DNA 合成,抑制细胞增殖,替匹嘧啶抑制曲氟尿苷的代谢降解,维持有效血药浓度。国际多中心 RECOURSE 研究和 TERRA 研究均显示 TAS-102 可降低疾病进展风险和死亡风险^[251-252]。常见的不良反应以骨髓抑制为主,而手足综合征、腹泻等非血液学不良反应发生率较低。目前 TAS-102 已获批用于既往接受过氟尿嘧啶、奥沙利铂和伊立替康为基础的化疗,以及无论既往是否接受过抗 VEGF 治疗或抗 EGFR 治疗(RAS 野生型)的转移性结直肠癌患者。

★雷替曲塞

雷替曲塞 3 mg/m² 静脉输注,每 3 周重复

雷替曲塞为抗代谢类叶酸类似物,特异性地抑制胸苷酸合成酶,导致 DNA 断裂和细胞凋亡。目前已批准在患者无法接受联合化疗时,雷替曲塞单药用于治疗不适合 5-FU/LV 的晚期结直肠癌患者。主要的不良反应是对胃肠道、血液系统及肝功能的影响。

附录 6 免疫检查点治疗

★帕博利珠单抗克隆抗体 2 mg/kg,第 1 天,每 3 周重复

★纳武利尤单抗克隆抗体 3 mg/kg,第 1 天,每 2 周重复

★特瑞普利单抗克隆抗体 3 mg/kg,第 1 天,每 2 周重复

★信迪利单抗克隆抗体 200 mg/次,第 1 天,每 3 周重复

★卡瑞利珠单抗克隆抗体 200 mg/次,第 1 天,每 2 周重复

附录 7 直肠癌的联合放化疗

放疗剂量总量 45~54 Gy,采用常规分割剂量(通常为 35 d),同时接受如下方案化疗:

★不伴有肝转移:卡培他滨 850~1 000 mg/m²,每日 2 次,每周 5 d

★伴有肝转移:

☆奥沙利铂每周 60 mg/m²,共 6 周;5-FU 200 mg/m²,第 1~40 天

☆伊立替康 50 mg/m²,第 1、8、15、22 天;5-FU 200 mg/m²,第 1~33 天

☆奥沙利铂每周 d1 60 mg/m²,卡培他滨 650 mg/m²,每日 2 次,d1~d5,共 6 周

附录 8 肝动脉和结直肠肿瘤区域联合灌注化疗

奥沙利铂 75 mg/m²,FUDR 650 mg/m²,丝裂霉素 8 mg/m²

采用股动脉穿刺法(Seldinger 法),经动脉导管超选择插管至结直肠肿瘤主要的滋养动脉内注入化疗 1/2 剂量;再超选择插管至肝固有动脉或肝肿瘤的滋养动脉内注入 1/2 剂量。

《中国结直肠癌肝转移诊断和综合治疗指南(2023 版)》修订专家名单(以姓氏汉语拼音排序)

编写组组长:

樊 嘉 复旦大学附属中山医院

顾 晋 北京大学肿瘤医院

贾宝庆 中国人民解放军总医院

李 进 同济大学附属东方医院

秦新裕 复旦大学附属中山医院

王锡山 中国医学科学院肿瘤医院

许剑民 复旦大学附属中山医院

徐瑞华 中山大学附属肿瘤医院

叶颖江 北京大学人民医院

张苏展 浙江大学医学院附属第二医院

张忠涛 首都医科大学附属北京友谊医院

编写组成员:

巴 一 天津医科大学附属肿瘤医院

卜建红 中华胃肠外科杂志

蔡建辉 河北省人民医院

蔡建强 中国医学科学院肿瘤医院

蔡三军 复旦大学附属肿瘤医院

曾 珊 中南大学湘雅医院

曾昭冲 复旦大学附属中山医院

陈 功 广州中山大学附属肿瘤医院

陈 凇 中国人民解放军总医院

陈 敏 中华消化外科杂志

陈子华 中南大学湘雅医院

陈宗祐 复旦大学附属华山医院

程洁敏 复旦大学附属中山医院

程 勇 重庆医科大学附属第一医院

池 畔 福建医科大学附属协和医院

崔滨滨 哈尔滨医科大学附属肿瘤医院

戴广海 中国人民解放军总医院

戴 勇 山东大学齐鲁医院

邓艳红 中山大学附属第六医院

丁克峰 浙江大学医学院附属第二医院

房学东 吉林大学中日联谊医院

傅传刚 同济大学附属东方医院

龚建平 华中科技大学附属同济医院

郝纯毅 北京大学肿瘤医院

何裕隆 中山大学附属第一医院

黄忠诚 湖南省人民医院

季加孚 北京大学肿瘤医院

姜可伟 北京大学人民医院

金 晶 中国医学科学院肿瘤医院

孔大陆 天津医科大学附属肿瘤医院

兰 平 中山大学附属第六医院

李德川 浙江省肿瘤医院

李国立 南京军区南京总医院

李乐平 山东省立医院

李云峰 云南省肿瘤医院

李志霞 首都医科大学北京同仁医院

梁后杰 陆军军医大学第一附属医院

林 锋 中山大学附属第六医院

林建江 浙江大学医学院附属第一医院

林小燕 福建医科大学附属协和医院

刘洪俊 山东省立医院

刘天舒 复旦大学附属中山医院

刘云鹏 中国医科大学附属第一医院
 潘宏铭 浙江大学医学院附属邵逸夫医院
 潘志忠 中山大学附属肿瘤医院
 裴海平 中南大学湘雅医院
 彭 涛 广西医科大学第一附属医院
 任 黎 复旦大学附属中山医院
 沈 琳 北京大学肿瘤医院
 宋 纯 同济大学附属东方医院
 宋天强 天津医科大学附属肿瘤医院
 苏向前 北京大学肿瘤医院
 孙益红 复旦大学附属中山医院
 陶 敏 苏州大学附属第一医院
 田利国 中国实用外科杂志
 童卫东 陆军军医大学大坪医院
 万德森 中山大学肿瘤医院
 汪建平 中山大学附属第六医院
 王贵英 河北医科大学第四医院
 王贵玉 哈尔滨医科大学附属第二医院
 王海江 新疆医科大学附属肿瘤医院
 王建华 复旦大学附属中山医院
 王 健 复旦大学附属中山医院
 王 杉 北京大学人民医院
 王 新 空军军医大学西京消化病医院
 王雅杰 海军军医大学附属长海医院
 王 屹 北京大学人民医院
 王自强 四川大学华西医院
 韦 烨 复旦大学附属中山医院
 魏 东 中国人民解放军第 150 医院
 夏 锋 陆军军医大学第一附属医院
 夏建国 江苏省人民医院
 夏立建 山东省千佛山医院
 谢 丹 中山大学附属肿瘤防治中心
 邢宝才 北京大学肿瘤医院
 熊 斌 武汉大学中南医院
 徐建明 中国人民解放军第 307 医院
 徐 农 浙江大学医学院附属第一医院
 徐 烨 复旦大学附属肿瘤医院
 徐泽宽 江苏省人民医院
 徐忠法 山东省医学科学院附属医院
 杨树军 河南省肿瘤医院
 姚宏伟 首都医科大学附属北京友谊医院
 叶青海 复旦大学附属中山医院
 余佩武 陆军军医大学第一附属医院
 余一祎 复旦大学附属中山医院
 袁 瑛 浙江大学医学院附属第二医院
 张 俊 上海交通大学医学院附属瑞金医院
 张克亮 湖北省肿瘤医院
 张 卫 海军军医大学附属长海医院
 张小田 北京大学肿瘤医院
 张艳桥 哈尔滨医科大学附属肿瘤医院

张有成 兰州大学第二医院
 章 真 复旦大学附属肿瘤医院
 赵青川 空军军医大学西京消化病医院
 赵 任 上海交通大学医学院附属瑞金医院
 郑 树 浙江大学医学院附属第二医院
 周爱萍 中国医学科学院肿瘤医院
 周 波 复旦大学附属中山医院
 周 俭 复旦大学附属中山医院
 周总光 四川大学华西医院
 朱德祥 复旦大学附属中山医院

执笔人:

朱德祥 任 黎 许剑民

利益冲突 所有作者均声明不存在利益冲突

参 考 文 献

- [1] Adam R, Vinet E. Regional treatment of metastasis: surgery of colorectal liver metastases[J]. Ann Oncol, 2004, 15 (Suppl 4):iv103-iv106. DOI:10.1093/annonc/mdh912.
- [2] Siegel RL, Miller KD, Fedewa SA, et al. Colorectal cancer statistics, 2017[J]. CA Cancer J Clin, 2017, 67(3):177-193. DOI:10.3322/caac.21395.
- [3] Giannis D, Sideris G, Kakos CD, et al. The role of liver transplantation for colorectal liver metastases: a systematic review and pooled analysis[J]. Transplant Rev (Orlando), 2020, 34(4):100570. DOI:10.1016/j.trre.2020.100570.
- [4] Taniai N, Akimaru K, Yoshida H, et al. Surgical treatment for better prognosis of patients with liver metastases from colorectal cancer[J]. Hepatogastroenterology, 2007, 54(78): 1805-1809.
- [5] Qin S, Liu GJ, Huang MJ, et al. The local efficacy and influencing factors of ultrasound-guided percutaneous microwave ablation in colorectal liver metastases: a review of a 4-year experience at a single center[J]. Int J Hyperthermia, 2019, 36(1):36-43. DOI:10.1080/02656736.2018.1528511.
- [6] Arru M, Aldrighetti L, Castoldi R, et al. Analysis of prognostic factors influencing long-term survival after hepatic resection for metastatic colorectal cancer[J]. World J Surg, 2008, 32(1):93-103. DOI:10.1007/s00268-007-9285-y.
- [7] Vibert E, Canedo L, Adam R. Strategies to treat primary unresectable colorectal liver metastases[J]. Semin Oncol, 2005, 32(6 Suppl 8):33-39. DOI:10.1053/j.seminoncol.2005.07.015.
- [8] Hong YS, Song SY, Lee SI, et al. A phase II trial of capecitabine in previously untreated patients with advanced and/or metastatic gastric cancer[J]. Ann Oncol, 2004, 15(9):1344-1347. DOI:10.1093/annonc/mdh343.
- [9] Stewart CL, Warner S, Ito K, et al. Cytoreduction for colorectal metastases: liver, lung, peritoneum, lymph nodes, bone, brain. When does it palliate, prolong survival, and potentially cure? [J]. Curr Probl Surg, 2018, 55(9):330-379. DOI:10.1067/j.cpsurg.2018.08.004.
- [10] de Jong MC, Pulitano C, Ribero D, et al. Rates and patterns of recurrence following curative intent surgery for colorectal liver metastasis: an international multi-institutional analysis of 1669 patients[J]. Ann Surg, 2009, 250(3): 440-448. DOI:10.1097/SLA.0b013e3181b4539b.

- [11] Norén A, Sandström P, Gunnarsdóttir K, et al. Identification of inequalities in the selection of liver surgery for colorectal liver metastases in Sweden[J]. *Scand J Surg*, 2018, 107(4):294-301. DOI:10.1177/1457496918766706.
- [12] Margonis GA, Sergentanis TN, Ntanasis-Stathopoulos I, et al. Impact of surgical margin width on recurrence and overall survival following R0 hepatic resection of colorectal metastases: a systematic review and Meta-analysis[J]. *Ann Surg*, 2018, 267(6):1047-1055. DOI:10.1097/SLA.0000000000002552.
- [13] Giuliani F, Ardito F, Vellone M, et al. Role of the surgeon as a variable in long-term survival after liver resection for colorectal metastases[J]. *J Surg Oncol*, 2009, 100(7):538-545. DOI:10.1002/jso.21393.
- [14] Yang AD, Brouquet A, Vauthey JN. Extending limits of resection for metastatic colorectal cancer: risk benefit ratio[J]. *J Surg Oncol*, 2010, 102(8):996-1001. DOI:10.1002/jso.21701.
- [15] Timmerman RD, Bizakis CS, Pass HI, et al. Local surgical, ablative, and radiation treatment of metastases[J]. *CA Cancer J Clin*, 2009, 59(3):145-170. DOI:10.3322/caac.20013.
- [16] Lv Y, Feng QY, Wei Y, et al. Benefits of multi-disciplinary treatment strategy on survival of patients with colorectal cancer liver metastasis[J]. *Clin Transl Med*, 2020, 10(3):e121. DOI:10.1002/ctm2.121.
- [17] Adam R, de Gramont A, Figueras J, et al. Managing synchronous liver metastases from colorectal cancer: a multi-disciplinary international consensus[J]. *Cancer Treat Rev*, 2015, 41(9):729-741. DOI:10.1016/j.ctrv.2015.06.006.
- [18] Bipat S, van Leeuwen MS, Ijzermans JN, et al. Evidence-based guideline on management of colorectal liver metastases in the Netherlands[J]. *Neth J Med*, 2007, 65(1):5-14.
- [19] Monteil J, Le Brun-Ly V, Cachin F, et al. Comparison of ¹⁸FDG-PET/CT and conventional follow-up methods in colorectal cancer: a randomised prospective study[J]. *Dig Liver Dis*, 2021, 53(2):231-237. DOI:10.1016/j.dld.2020.10.012.
- [20] Gouriet F, Tissot-Dupont H, Casalta JP, et al. FDG-PET/CT incidental detection of cancer in patients investigated for infective endocarditis[J]. *Front Med (Lausanne)*, 2020, 7:535. DOI:10.3389/fmed.2020.00535.
- [21] Coenegrachts K, De Geeter F, ter Beek L, et al. Comparison of MRI (including SS SE-EPI and SPIO-enhanced MRI) and FDG-PET/CT for the detection of colorectal liver metastases[J]. *Eur Radiol*, 2009, 19(2):370-379. DOI:10.1007/s00330-008-1163-y.
- [22] Jones OM, Rees M, John TG, et al. Biopsy of resectable colorectal liver metastases causes tumour dissemination and adversely affects survival after liver resection[J]. *Br J Surg*, 2005, 92(9):1165-1168. DOI:10.1002/bjs.4888.
- [23] Koshariya M, Jagad RB, Kawamoto J, et al. An update and our experience with metastatic liver disease[J]. *Hepatogastroenterology*, 2007, 54(80):2232-2239.
- [24] Komborozos VA, Skrekas GJ, Pissiotis CA. The contribution of follow-up programs in the reduction of mortality of rectal cancer recurrences[J]. *Dig Surg*, 2001, 18(5):403-408. DOI:10.1159/000050182.
- [25] Tsikitis VL, Malireddy K, Green EA, et al. Postoperative surveillance recommendations for early stage colon cancer based on results from the clinical outcomes of surgical therapy trial[J]. *J Clin Oncol*, 2009, 27(22):3671-3676. DOI:10.1200/JCO.2008.20.7050.
- [26] Pfister DG, Benson AB, Somerfield MR. Clinical practice. Surveillance strategies after curative treatment of colorectal cancer[J]. *N Engl J Med*, 2004, 350(23):2375-2382. DOI:10.1056/NEJMcp010529.
- [27] Locker GY, Hamilton S, Harris J, et al. ASCO 2006 update of recommendations for the use of tumor markers in gastrointestinal cancer[J]. *J Clin Oncol*, 2006, 24(33):5313-5327. DOI:10.1200/JCO.2006.08.2644.
- [28] Desch CE, Benson AB, Somerfield MR, et al. Colorectal cancer surveillance: 2005 update of an American Society of Clinical Oncology practice guideline[J]. *J Clin Oncol*, 2005, 23(33):8512-8519. DOI:10.1200/JCO.2005.04.0063.
- [29] Rex DK, Kahi CJ, Levin B, et al. Guidelines for colonoscopy surveillance after cancer resection: a consensus update by the American Cancer Society and the US Multi-Society Task Force on Colorectal Cancer[J]. *Gastroenterology*, 2006, 130(6):1865-1871. DOI:10.1053/j.gastro.2006.03.013.
- [30] Rex DK, Kahi CJ, Levin B, et al. Guidelines for colonoscopy surveillance after cancer resection: a consensus update by the American Cancer Society and US Multi-Society Task Force on Colorectal Cancer[J]. *CA Cancer J Clin*, 2006, 56(3):160-167, 185-186. DOI:10.3322/canjclin.56.3.160.
- [31] Modest DP, Ricard I, Heinemann V, et al. Outcome according to KRAS-, NRAS- and BRAF-mutation as well as KRAS mutation variants: pooled analysis of five randomized trials in metastatic colorectal cancer by the AIO colorectal cancer study group[J]. *Ann Oncol*, 2016, 27(9):1746-1753. DOI:10.1093/annonc/mdw261.
- [32] Therkildsen C, Bergmann TK, Henriksen-Schnack T, et al. The predictive value of KRAS, NRAS, BRAF, PIK3CA and PTEN for anti-EGFR treatment in metastatic colorectal cancer: a systematic review and meta-analysis[J]. *Acta Oncol*, 2014, 53(7):852-864. DOI:10.3109/0284186X.2014.895036.
- [33] Schirripa M, Cremolini C, Loupakis F, et al. Role of NRAS mutations as prognostic and predictive markers in metastatic colorectal cancer[J]. *Int J Cancer*, 2015, 136(1):83-90. DOI:10.1002/ijc.28955.
- [34] Brudvik KW, Mise Y, Chung MH, et al. RAS mutation predicts positive resection margins and narrower resection margins in patients undergoing resection of colorectal liver metastases[J]. *Ann Surg Oncol*, 2016, 23(8):2635-2643. DOI:10.1245/s10434-016-5187-2.
- [35] Passot G, Chun YS, Kopetz SE, et al. Prognostic factors after resection of colorectal liver metastases following preoperative second-line chemotherapy: impact of RAS mutations[J]. *Eur J Surg Oncol*, 2016, 42(9):1378-1384. DOI:10.1016/j.ejso.2016.02.249.
- [36] Margonis GA, Buettner S, Andreatos N, et al. Anatomical resections improve disease-free survival in patients with KRAS-mutated colorectal liver metastases[J]. *Ann Surg*, 2017, 266(4):641-649. DOI:10.1097/SLA.0000000000002367.
- [37] Sorich MJ, Wiese MD, Rowland A, et al. Extended RAS mutations and anti-EGFR monoclonal antibody survival benefit in metastatic colorectal cancer: a meta-analysis of randomized, controlled trials[J]. *Ann Oncol*, 2015, 26(1):13-21. DOI:10.1093/annonc/mdu378.
- [38] Mao C, Yang ZY, Hu XF, et al. PIK3CA exon 20 mutations as a potential biomarker for resistance to anti-EGFR mono-

- clonal antibodies in KRAS wild-type metastatic colorectal cancer: a systematic review and meta-analysis[J]. *Ann Oncol*, 2012,23(6):1518-1525. DOI:10.1093/annonc/mdr464.
- [39] Kopetz S, Grothey A, Yaeger R, et al. Encorafenib, binimetinib, and cetuximab in BRAF V600E-Mutated Colorectal Cancer[J]. *N Engl J Med*, 2019,381(17):1632-1643. DOI:10.1056/NEJMoa1908075.
- [40] van Cutsem E, Huijberts S, Grothey A, et al. Binimetinib, encorafenib, and cetuximab triplet therapy for patients with BRAF V600E-mutant metastatic colorectal cancer: safety lead-in results from the phase III BEACON colorectal cancer study[J]. *J Clin Oncol*, 2019,37(17):1460-1469. DOI:10.1200/JCO.18.02459.
- [41] Guren TK, Thomsen M, Kure EH, et al. Cetuximab in treatment of metastatic colorectal cancer: final survival analyses and extended RAS data from the NORDIC-VII study[J]. *Br J Cancer*, 2017,116(10):1271-1278. DOI:10.1038/bjc.2017.93.
- [42] Sinicrope FA, Shi Q, Allegra CJ, et al. Association of DNA mismatch repair and mutations in BRAF and KRAS with survival after recurrence in stage III colon cancers: a secondary analysis of 2 randomized clinical trials[J]. *JAMA Oncol*, 2017,3(4):472-480. DOI:10.1001/jamaoncol.2016.5469.
- [43] Pikoulis E, Margonis GA, Andreatos N, et al. Prognostic role of BRAF mutations in colorectal cancer liver metastases [J]. *Anticancer Res*, 2016,36(9):4805-4811. DOI:10.21873/anticancer.11040.
- [44] Moreira L, Balaguer F, Lindor N, et al. Identification of lynch syndrome among patients with colorectal cancer[J]. *JAMA*, 2012,308(15):1555-1565. DOI:10.1001/jama.2012.13088.
- [45] Umar A, Boland CR, Terdiman JP, et al. Revised Bethesda guidelines for hereditary nonpolyposis colorectal cancer (lynch syndrome) and microsatellite instability[J]. *J Natl Cancer Inst*, 2004,96(4):261-268. DOI:10.1093/jnci/djh034.
- [46] Buchanan DD, Clendenning M, Rosty C, et al. Tumor testing to identify lynch syndrome in two Australian colorectal cancer cohorts[J]. *J Gastroenterol Hepatol*, 2017,32(2):427-438. DOI:10.1111/jgh.13468.
- [47] Chen SN, Watson P, Parmigiani G. Accuracy of MSI testing in predicting germline mutations of MSH2 and MLH1: a case study in Bayesian meta-analysis of diagnostic tests without a gold standard [J]. *Biostatistics*, 2005,6(3):450-464. DOI:10.1093/biostatistics/kxi021.
- [48] Hempelmann JA, Lockwood CM, Konnick EQ, et al. Microsatellite instability in prostate cancer by PCR or next-generation sequencing[J]. *J Immunother Cancer*, 2018,6(1):29. DOI:10.1186/s40425-018-0341-y.
- [49] Stelloo E, Jansen AML, Osse EM, et al. Practical guidance for mismatch repair-deficiency testing in endometrial cancer [J]. *Ann Oncol*, 2017,28(1):96-102. DOI:10.1093/annonc/mdw542.
- [50] Marsh S, Hoskins JM. Irinotecan pharmacogenomics[J]. *Pharmacogenomics*, 2010,11(7):1003-1010. DOI:10.2217/pgs.10.95.
- [51] Barbarino JM, Haidar CE, Klein TE, et al. PharmGKB summary: very important pharmacogene information for UGT1A1 [J]. *Pharmacogenet Genomics*, 2014,24(3):177-183. DOI:10.1097/FPC.0000000000000024.
- [52] Hoskins JM, Goldberg RM, Qu PP, et al. UGT1A1*28 genotype and irinotecan-induced neutropenia: dose matters[J]. *J Natl Cancer Inst*, 2007,99(17):1290-1295. DOI:10.1093/jnci/djm115.
- [53] Guler I, Askan G, Klostergaard J, et al. Precision medicine for metastatic colorectal cancer: an evolving era[J]. *Expert Rev Gastroenterol Hepatol*, 2019,13(10):919-931. DOI:10.1080/17474124.2019.1663174.
- [54] Allgauer M, Budczies J, Christopoulos P, et al. Implementing tumor mutational burden (TMB) analysis in routine diagnostics-a primer for molecular pathologists and clinicians[J]. *Transl Lung Cancer Res*, 2018,7(6):703-715. DOI:10.21037/tlcr.2018.08.14.
- [55] Cocco E, Scaltriti M, Drilon A. NTRK fusion-positive cancers and TRK inhibitor therapy[J]. *Nat Rev Clin Oncol*, 2018,15(12):731-747. DOI:10.1038/s41571-018-0113-0.
- [56] Artale S, Sartore-Bianchi A, Veronese SM, et al. Mutations of KRAS and BRAF in primary and matched metastatic sites of colorectal cancer[J]. *J Clin Oncol*, 2008,26(25):4217-4219. DOI:10.1200/JCO.2008.18.7286.
- [57] Etienne-Grimaldi MC, Formento JL, Francoual M, et al. K-Ras mutations and treatment outcome in colorectal cancer patients receiving exclusive fluoropyrimidine therapy[J]. *Clin Cancer Res*, 2008,14(15):4830-4835. DOI:10.1158/1078-0432.CCR-07-4906.
- [58] Knijn N, Mekenkamp LJ, Klomp M, et al. KRAS mutation analysis: a comparison between primary tumours and matched liver metastases in 305 colorectal cancer patients[J]. *Br J Cancer*, 2011,104(6):1020-1026. DOI:10.1038/bjc.2011.26.
- [59] Okuno K. Surgical treatment for digestive cancer. Current issues-colon cancer[J]. *Dig Surg*, 2007,24(2):108-114. DOI:10.1159/000101897.
- [60] Borschitz T, Wachtlin D, Möhler M, et al. Neoadjuvant chemoradiation and local excision for T2-3 rectal cancer[J]. *Ann Surg Oncol*, 2008,15(3):712-720. DOI:10.1245/s10434-007-9732-x.
- [61] Read TE, Andujar JE, Caushaj PF, et al. Neoadjuvant therapy for rectal cancer: histologic response of the primary tumor predicts nodal status[J]. *Dis Colon Rectum*, 2004,47(6):825-831. DOI:10.1007/s10350-004-0535-x.
- [62] Chau I, Chan S, Cunningham D. Overview of preoperative and postoperative therapy for colorectal cancer: the European and United States perspectives[J]. *Clin Colorectal Cancer*, 2003,3(1):19-33. DOI:10.3816/CCC.2003.n.009.
- [63] Peeters KC, Marijnen CA, Nagtegaal ID, et al. The TME trial after a median follow-up of 6 years: increased local control but no survival benefit in irradiated patients with resectable rectal carcinoma[J]. *Ann Surg*, 2007,246(5):693-701. DOI:10.1097/01.sla.0000257358.56863.ce.
- [64] van Gijn W, Marijnen CA, Nagtegaal ID, et al. Preoperative radiotherapy combined with total mesorectal excision for resectable rectal cancer: 12-year follow-up of the multicentre, randomised controlled TME trial[J]. *Lancet Oncol*, 2011,12(6):575-582. DOI:10.1016/S1470-2045(11)70097-3.
- [65] Kennecke H, Lim H, Woods R, et al. Outcomes of unselected patients with pathologic T3N0 rectal cancer[J]. *Radiother Oncol*, 2012,105(2):214-219. DOI:10.1016/j.radonc.2012.09.021.

- [66] Cercek A, Roxburgh CSD, Strombom P, et al. Adoption of total neoadjuvant therapy for locally advanced rectal cancer[J]. *JAMA Oncol*, 2018, 4(6):e180071. DOI:10.1001/jamaoncol.2018.0071.
- [67] Petrelli F, Trevisan F, Cabiddu M, et al. Total neoadjuvant therapy in rectal cancer: a systematic review and meta-analysis of treatment outcomes[J]. *Ann Surg*, 2020, 271(3): 440-448. DOI:10.1097/SLA.0000000000003471.
- [68] Xu J, Zhong Y, Weixin N, et al. Preoperative hepatic and regional arterial chemotherapy in the prevention of liver metastasis after colorectal cancer surgery[J]. *Ann Surg*, 2007, 245(4):583-590. DOI:10.1097/01.sla.0000250453.34507.d3.
- [69] Chang WJ, Wei Y, Ren L, et al. Randomized controlled trial of intraportal chemotherapy combined with adjuvant chemotherapy (mFOLFOX6) for stage II and III colon cancer [J]. *Ann Surg*, 2016, 263(3):434-439. DOI:10.1097/SLA.0000000000001374.
- [70] Sugihara K, Ohtsu A, Shimada Y, et al. Safety analysis of FOLFOX4 treatment in colorectal cancer patients: a comparison between two Asian studies and four Western studies[J]. *Clin Colorectal Cancer*, 2012, 11(2):127-137. DOI: 10.1016/j.clcc.2011.09.001.
- [71] Rodríguez-Moranta F, Saló J, Arcusa A, et al. Postoperative surveillance in patients with colorectal cancer who have undergone curative resection: a prospective, multicenter, randomized, controlled trial[J]. *J Clin Oncol*, 2006, 24(3): 386-393. DOI:10.1200/JCO.2005.02.0826.
- [72] André T, Boni C, Navarro M, et al. Improved overall survival with oxaliplatin, fluorouracil, and leucovorin as adjuvant treatment in stage II or III colon cancer in the MOSAIC trial[J]. *J Clin Oncol*, 2009, 27(19):3109-3116. DOI: 10.1200/JCO.2008.20.6771.
- [73] Kuebler JP, Wieand HS, O'Connell MJ, et al. Oxaliplatin combined with weekly bolus fluorouracil and leucovorin as surgical adjuvant chemotherapy for stage II and III colon cancer: results from NSABP C-07[J]. *J Clin Oncol*, 2007, 25(16):2198-2204. DOI:10.1200/JCO.2006.08.2974.
- [74] Baxter NN, Kennedy EB, Bergsland E, et al. Adjuvant therapy for stage II colon cancer: ASCO guideline update[J]. *J Clin Oncol*, 2022, 40(8): 892-910. DOI: 10.1200/JCO.21.02538.
- [75] Tveit KM, Wiig JN, Olsen DR, et al. Combined modality treatment including intraoperative radiotherapy in locally advanced and recurrent rectal cancer[J]. *Radiother Oncol*, 1997, 44(3):277-282. DOI:10.1016/s0167-8140(97)00070-4.
- [76] Yu TK, Bhosale PR, Crane CH, et al. Patterns of locoregional recurrence after surgery and radiotherapy or chemoradiation for rectal cancer[J]. *Int J Radiat Oncol Biol Phys*, 2008, 71(4):1175-1180. DOI:10.1016/j.ijrobp.2007.11.018.
- [77] Fennell ML, Das IP, Clauser S, et al. The organization of multidisciplinary care teams: modeling internal and external influences on cancer care quality[J]. *J Natl Cancer Inst Monogr*, 2010, 2010(40):72-80. DOI:10.1093/jncimonographs/lgq010.
- [78] Rabinowitz B. Interdisciplinary breast cancer care: declaring and improving the standard[J]. *Oncology (Williston Park)*, 2004, 18(10):1263-1270, 1275.
- [79] Nordlinger B, Vauthey JN, Poston G, et al. The timing of chemotherapy and surgery for the treatment of colorectal liver metastases[J]. *Clin Colorectal Cancer*, 2010, 9(4):212-218. DOI:10.3816/CCC.2010.n.031.
- [80] Wright FC, de Vito C, Langer B, et al. Multidisciplinary cancer conferences: a systematic review and development of practice standards[J]. *Eur J Cancer*, 2007, 43(6):1002-1010. DOI:10.1016/j.ejca.2007.01.025.
- [81] Jung SM, Hong YS, Kim TW, et al. Impact of a multidisciplinary team approach for managing advanced and recurrent colorectal cancer[J]. *World J Surg*, 2018, 42(7):2227-2233. DOI:10.1007/s00268-017-4409-5.
- [82] Davies AR, Deans DA, Penman I, et al. The multidisciplinary team meeting improves staging accuracy and treatment selection for gastro-esophageal cancer[J]. *Dis Esophagus*, 2006, 19(6):496-503. DOI:10.1111/j.1442-2050.2006.00629.x.
- [83] Fleissig A. Multidisciplinary teams in cancer care: are they effective in the UK?[J]. *Lancet Oncol*, 2006, 7(11):935-943. DOI:10.1016/S1470-2045(06)70940-8.
- [84] Gabel M, Hilton NE, Nathanson SD. Multidisciplinary breast cancer clinics. Do they work?[J]. *Cancer*, 1997, 79(12):2380-2384.
- [85] Schiergens TS, von Einem J, Thomas MN, et al. Multidisciplinary treatment of colorectal liver metastases[J]. *Minerva Med*, 2017, 108(6):527-546. DOI: 10.23736/S0026-4806.17.05371-X.
- [86] Carter S, Garside P, Black A. Multidisciplinary team working, clinical networks, and chambers; opportunities to work differently in the NHS[J]. *Qual Saf Health Care*, 2003, 12(Suppl 1):i25-i28. DOI:10.1136/qhc.12.suppl_1.i25.
- [87] Rummans TA, Clark MM, Sloan JA, et al. Impacting quality of life for patients with advanced cancer with a structured multidisciplinary intervention: a randomized controlled trial[J]. *J Clin Oncol*, 2006, 24(4):635-642. DOI:10.1200/JCO.2006.06.209.
- [88] Du CZ, Li J, Cai Y, et al. Effect of multidisciplinary team treatment on outcomes of patients with gastrointestinal malignancy[J]. *World J Gastroenterol*, 2011, 17(15):2013-2018. DOI:10.3748/wjg.v17.i15.2013.
- [89] MacDermid E, Hooton G, MacDonald M, et al. Improving patient survival with the colorectal cancer multi-disciplinary team[J]. *Colorectal Dis*, 2009, 11(3):291-295. DOI: 10.1111/j.1463-1318.2008.01580.x.
- [90] Obias VJ, Reynolds HL. Multidisciplinary teams in the management of rectal cancer[J]. *Clin Colon Rectal Surg*, 2007, 20(3):143-147. DOI:10.1055/s-2007-984858.
- [91] Wanis KN, Pineda-Solis K, Tun-Abraham ME, et al. Management of colorectal cancer with synchronous liver metastases: impact of multidisciplinary case conference review [J]. *Hepatobiliary Surg Nutr*, 2017, 6(3):162-169. DOI: 10.21037/hbsn.2017.01.01.
- [92] Lan YT, Jiang JK, Chang SC, et al. Improved outcomes of colorectal cancer patients with liver metastases in the era of the multidisciplinary teams[J]. *Int J Colorectal Dis*, 2016, 31(2):403-411. DOI:10.1007/s00384-015-2459-4.
- [93] Look Hong NJ, Gagliardi AR, Bronskill SE, et al. Multidisciplinary cancer conferences: exploring obstacles and facilitators to their implementation[J]. *J Oncol Pract*, 2010, 6(2): 61-68. DOI:10.1200/JOP.091085.
- [94] Swan PJ, Welsh FK, Chandrakumaran K, et al. Long-term survival following delayed presentation and resection of colorectal liver metastases[J]. *Br J Surg*, 2011, 98(9):1309-

1317. DOI:10.1002/bjs.7527.
- [95] Rahbari NN, Birgin E, Bork U, et al. Anterior approach vs conventional hepatectomy for resection of colorectal liver metastasis: a randomized clinical trial[J]. *JAMA Surg*, 2021, 156(1):31-40. DOI:10.1001/jamasurg.2020.5050.
- [96] Datta J, Narayan RR, Kemeny NE, et al. Role of hepatic artery infusion chemotherapy in treatment of initially unresectable colorectal liver metastases: a review[J]. *JAMA Surg*, 2019, 154(8):768-776. DOI:10.1001/jamasurg.2019.1694.
- [97] André T, Shiu KK, Kim TW, et al. Pembrolizumab in microsatellite-instability-high advanced colorectal cancer[J]. *N Engl J Med*, 2020, 383(23):2207-2218. DOI:10.1056/NEJMoa2017699.
- [98] Kanani A, Veen T, Søreide K. Neoadjuvant immunotherapy in primary and metastatic colorectal cancer[J]. *Br J Surg*, 2021, 108(12):1417-1425. DOI:10.1093/bjs/znab342.
- [99] Mattar RE, Al-Alem F, Simoneau E, et al. Preoperative selection of patients with colorectal cancer liver metastasis for hepatic resection[J]. *World J Gastroenterol*, 2016, 22(2):567-581. DOI:10.3748/wjg.v22.i2.567.
- [100] Bentrem DJ, Dematteo RP, Blumgart LH. Surgical therapy for metastatic disease to the liver[J]. *Annu Rev Med*, 2005, 56:139-156. DOI:10.1146/annurev.med.56.082103.104630.
- [101] Akgül Ö, Çetinkaya E, Ersöz Ş, et al. Role of surgery in colorectal cancer liver metastases[J]. *World J Gastroenterol*, 2014, 20(20):6113-6122. DOI:10.3748/wjg.v20.i20.6113.
- [102] Mayo SC, Pawlik TM. Current management of colorectal hepatic metastasis[J]. *Expert Rev Gastroenterol Hepatol*, 2009, 3(2):131-144. DOI:10.1586/egh.09.8.
- [103] Poston GJ. Radiofrequency ablation of colorectal liver metastases: where are we really going?[J]. *J Clin Oncol*, 2005, 23(7):1342-1344. DOI:10.1200/JCO.2005.10.911.
- [104] Hur H, Ko YT, Min BS, et al. Comparative study of resection and radiofrequency ablation in the treatment of solitary colorectal liver metastases[J]. *Am J Surg*, 2009, 197(6):728-736. DOI:10.1016/j.amjsurg.2008.04.013.
- [105] Reuter NP, Woodall CE, Scoggins CR, et al. Radiofrequency ablation vs. resection for hepatic colorectal metastasis: therapeutically equivalent? [J]. *J Gastrointest Surg*, 2009, 13(3):486-491. DOI:10.1007/s11605-008-0727-0.
- [106] Zhu DX, Ren L, Wei Y, et al. Outcome of patients with colorectal liver metastasis: analysis of 1,613 consecutive cases [J]. *Ann Surg Oncol*, 2012, 19(9):2860-2868. DOI:10.1245/s10434-012-2356-9.
- [107] Sharma S, Camci C, Jabbour N. Management of hepatic metastasis from colorectal cancers: an update[J]. *J Hepatobiliary Pancreat Surg*, 2008, 15(6):570-580. DOI:10.1007/s00534-008-1350-x.
- [108] Khan AS, Garcia-Aroz S, Ansari MA, et al. Assessment and optimization of liver volume before major hepatic resection: current guidelines and a narrative review[J]. *Int J Surg*, 2018, 52:74-81. DOI:10.1016/j.ijsu.2018.01.042.
- [109] Bégin A, Martel G, Lapointe R, et al. Accuracy of preoperative automatic measurement of the liver volume by CT-scan combined to a 3D virtual surgical planning software (3DVSP)[J]. *Surg Endosc*, 2014, 28(12):3408-3412. DOI:10.1007/s00464-014-3611-x.
- [110] Yan TD, Padang R, Xia H, et al. Management of involved or close resection margins in 120 patients with colorectal liver metastases: edge cryotherapy can achieve long-term survival[J]. *Am J Surg*, 2006, 191(6):735-742. DOI:10.1016/j.amjsurg.2005.05.055.
- [111] Blazer DG, Kishi Y, Maru DM, et al. Pathologic response to preoperative chemotherapy: a new outcome end point after resection of hepatic colorectal metastases[J]. *J Clin Oncol*, 2008, 26(33):5344-5351. DOI:10.1200/JCO.2008.17.5299.
- [112] Jaeck D. The significance of hepatic pedicle lymph nodes metastases in surgical management of colorectal liver metastases and of other liver malignancies[J]. *Ann Surg Oncol*, 2003, 10(9):1007-1011. DOI:10.1245/aso.2003.09.903.
- [113] Pulitanò C, Bodingbauer M, Aldrighetti L, et al. Colorectal liver metastasis in the setting of lymph node metastasis: defining the benefit of surgical resection[J]. *Ann Surg Oncol*, 2012, 19(2):435-442. DOI:10.1245/s10434-011-1902-1.
- [114] Margonis GA, Buettner S, Andreatos N, et al. Prognostic factors change over time after hepatectomy for colorectal liver metastases: a multi-institutional, international analysis of 1099 patients[J]. *Ann Surg*, 2019, 269(6):1129-1137. DOI:10.1097/SLA.0000000000002664.
- [115] Jaeck D, Oussoultzoglou E, Rosso E. Hepatectomy for colorectal metastases in the presence of extrahepatic disease [J]. *Surg Oncol Clin N Am*, 2007, 16(3):507-523, viii. DOI:10.1016/j.soc.2007.04.010.
- [116] Adam R, de Haas RJ, Wicherts DA, et al. Is hepatic resection justified after chemotherapy in patients with colorectal liver metastases and lymph node involvement? [J]. *J Clin Oncol*, 2008, 26(22):3672-3680. DOI:10.1200/JCO.2007.15.7297.
- [117] Zizzo M, Galeone C, Braglia L, et al. Long-term outcomes after surgical resection for synchronous or metachronous hepatic and pulmonary colorectal cancer metastases[J]. *Digestion*, 2020, 101(2):144-155. DOI:10.1159/000497223.
- [118] Pulitanò C, Bodingbauer M, Aldrighetti L, et al. Liver resection for colorectal metastases in presence of extrahepatic disease: results from an international multi-institutional analysis[J]. *Ann Surg Oncol*, 2011, 18(5):1380-1388. DOI:10.1245/s10434-010-1459-4.
- [119] Turrini O, Viret F, Guiramand J, et al. Strategies for the treatment of synchronous liver metastasis[J]. *Eur J Surg Oncol*, 2007, 33(6):735-740. DOI:10.1016/j.ejso.2007.02.025.
- [120] 赵东兵, 单毅, 王成峰, 等. 伴有同时性肝转移结直肠癌的外科治疗[J]. *中华肿瘤杂志*, 2007, 29(7):552-554. DOI:10.3760/j.issn:0253-3766.2007.07.018.
- [121] Chang GJ, Kaiser AM, Mills S, et al. Practice parameters for the management of colon cancer[J]. *Dis Colon Rectum*, 2012, 55(8):831-843. DOI:10.1097/DCR.0b013e3182567e13.
- [122] Capussotti L, Ferrero A, Viganò L, et al. Major liver resections synchronous with colorectal surgery[J]. *Ann Surg Oncol*, 2007, 14(1):195-201. DOI:10.1245/s10434-006-9055-3.
- [123] Wu YB, Mao AR, Wang HP, et al. Association of simultaneous vs delayed resection of liver metastasis with complications and survival among adults with colorectal cancer [J]. *JAMA Netw Open*, 2022, 5(9):e2231956. DOI:10.1001/jamanetworkopen.2022.31956.
- [124] Nakajima K, Takahashi S, Saito N, et al. Predictive factors for anastomotic leakage after simultaneous resection of synchronous colorectal liver metastasis[J]. *J Gastrointest Surg*, 2012, 16(4):821-827. DOI:10.1007/s11605-011-1782-5.

- [125] Hatwell C, Bretagnol F, Farges O, et al. Laparoscopic resection of colorectal cancer facilitates simultaneous surgery of synchronous liver metastases[J]. *Colorectal Dis*, 2013, 15(1):e21-e28. DOI:10.1111/codi.12068.
- [126] Schnitzbauer AA, Lang SA, Goessmann H, et al. Right portal vein ligation combined with in situ splitting induces rapid left lateral liver lobe hypertrophy enabling 2-staged extended right hepatic resection in small-for-size settings [J]. *Ann Surg*, 2012, 255(3):405-414. DOI: 10.1097/SLA.0b013e31824856f5.
- [127] Roxburgh CSD, Richards CH, Moug SJ, et al. Determinants of short- and long-term outcome in patients undergoing simultaneous resection of colorectal cancer and synchronous colorectal liver metastases[J]. *Int J Colorectal Dis*, 2012, 27(3):363-369. DOI:10.1007/s00384-011-1339-9.
- [128] Slupski M, Włodarczyk Z, Jasinski M, et al. Outcomes of simultaneous and delayed resections of synchronous colorectal liver metastases[J]. *Can J Surg*, 2009, 52(6):E241-E244.
- [129] Nanji S, MacKillop WJ, Wei X, et al. Simultaneous resection of primary colorectal cancer and synchronous liver metastases: a population-based study[J]. *Can J Surg*, 2017, 60(2):122-128. DOI:10.1503/cjs.008516.
- [130] de Jong MC, van Dam RM, Maas M, et al. The liver-first approach for synchronous colorectal liver metastasis: a 5-year single-centre experience[J]. *HPB (Oxford)*, 2011, 13(10):745-752. DOI:10.1111/j.1477-2574.2011.00372.x.
- [131] de Jong MC, Beckers RCJ, van Woerden V, et al. The liver-first approach for synchronous colorectal liver metastases: more than a decade of experience in a single centre[J]. *HPB (Oxford)*, 2018, 20(7):631-640. DOI: 10.1016/j.hpb.2018.01.005.
- [132] Brouquet A, Mortenson MM, Vauthey JN, et al. Surgical strategies for synchronous colorectal liver metastases in 156 consecutive patients: classic, combined or reverse strategy?[J]. *J Am Coll Surg*, 2010, 210(6):934-941. DOI:10.1016/j.jamcollsurg.2010.02.039.
- [133] Waisberg J, Ivankovics IG. Liver-first approach of colorectal cancer with synchronous hepatic metastases: a reverse strategy[J]. *World J Hepatol*, 2015, 7(11):1444-1449. DOI: 10.4254/wjh.v7.i11.1444.
- [134] Abbott DE, Cantor SB, Hu CY, et al. Optimizing clinical and economic outcomes of surgical therapy for patients with colorectal cancer and synchronous liver metastases[J]. *J Am Coll Surg*, 2012, 215(2):262-270. DOI: 10.1016/j.jamcollsurg.2012.03.021.
- [135] Kelly ME, Spolverato G, Lê GN, et al. Synchronous colorectal liver metastasis: a network meta-analysis review comparing classical, combined, and liver-first surgical strategies[J]. *J Surg Oncol*, 2015, 111(3):341-351. DOI: 10.1002/jso.23819.
- [136] Pelosi E, Deandreis D. The role of ¹⁸F-fluoro-deoxy-glucose positron emission tomography (FDG-PET) in the management of patients with colorectal cancer[J]. *Eur J Surg Oncol*, 2007, 33(1):1-6. DOI:10.1016/j.ejso.2006.10.020.
- [137] Tomlinson JS, Jarnagin WR, DeMatteo RP, et al. Actual 10-year survival after resection of colorectal liver metastases defines cure[J]. *J Clin Oncol*, 2007, 25(29):4575-4580. DOI: 10.1200/JCO.2007.11.0833.
- [138] Shoup M, Gonen M, D'Angelica M, et al. Volumetric analysis predicts hepatic dysfunction in patients undergoing major liver resection[J]. *J Gastrointest Surg*, 2003, 7(3):325-330. DOI:10.1016/s1091-255x(02)00370-0.
- [139] Sarpel U, Bonavia AS, Grucela A, et al. Does anatomic versus nonanatomic resection affect recurrence and survival in patients undergoing surgery for colorectal liver metastasis?[J]. *Ann Surg Oncol*, 2009, 16(2):379-384. DOI: 10.1245/s10434-008-0218-2.
- [140] Hammond JS, Guha IN, Beckingham IJ, et al. Prediction, prevention and management of postresection liver failure [J]. *Br J Surg*, 2011, 98(9):1188-1200. DOI:10.1002/bjs.7630.
- [141] Pawlik TM, Scoggins CR, Zorzi D, et al. Effect of surgical margin status on survival and site of recurrence after hepatic resection for colorectal metastases[J]. *Ann Surg*, 2005, 241(5):715-724. DOI:10.1097/01.sla.0000160703.75808.7d.
- [142] Ayez N, Lalmahomed ZS, Eggermont AM, et al. Outcome of microscopic incomplete resection (R1) of colorectal liver metastases in the era of neoadjuvant chemotherapy[J]. *Ann Surg Oncol*, 2012, 19(5):1618-1627. DOI: 10.1245/s10434-011-2114-4.
- [143] Pandanaboyana S, White A, Pathak S, et al. Impact of margin status and neoadjuvant chemotherapy on survival, recurrence after liver resection for colorectal liver metastasis[J]. *Ann Surg Oncol*, 2015, 22(1):173-179. DOI: 10.1245/s10434-014-3953-6.
- [144] Kokudo N, Miki Y, Sugai S, et al. Genetic and histological assessment of surgical margins in resected liver metastases from colorectal carcinoma: minimum surgical margins for successful resection[J]. *Arch Surg*, 2002, 137(7):833-840. DOI:10.1001/archsurg.137.7.833.
- [145] Adam R, Miller R, Pitombo M, et al. Two-stage hepatectomy approach for initially unresectable colorectal hepatic metastases[J]. *Surg Oncol Clin N Am*, 2007, 16(3):525-536, viii. DOI:10.1016/j.soc.2007.04.016.
- [146] Hasselgren K, Sandström P, Björnsson B. Role of associating liver partition and portal vein ligation for staged hepatectomy in colorectal liver metastases: a review[J]. *World J Gastroenterol*, 2015, 21(15):4491-4498. DOI: 10.3748/wjg.v21.i15.4491.
- [147] Björnsson B, Sparrelid E, Røsok B, et al. Associating liver partition and portal vein ligation for staged hepatectomy in patients with colorectal liver metastases—intermediate oncological results[J]. *Eur J Surg Oncol*, 2016, 42(4):531-537. DOI:10.1016/j.ejso.2015.12.013.
- [148] Chebaro A, Buc E, Durin T, et al. Liver venous deprivation or associating liver partition and portal vein ligation for staged hepatectomy?: a retrospective multicentric study [J]. *Ann Surg*, 2021, 274(5):874-880. DOI: 10.1097/SLA.0000000000005121.
- [149] Abbasi A, Rahnemai-Azar AA, Merath K, et al. Role of associating liver partition and portal vein ligation in staged hepatectomy (ALPPS)-strategy for colorectal liver metastases[J]. *Transl Gastroenterol Hepatol*, 2018, 3:66. DOI: 10.21037/tgh.2018.09.03.
- [150] Bertens KA, Hawel J, Lung K, et al. ALPPS: challenging the concept of unresectability—a systematic review[J]. *Int J Surg*, 2015, 13:280-287. DOI:10.1016/j.ijsu.2014.12.008.
- [151] Spampinato MG, Mandalá L, Quarta G, et al. One-stage, totally laparoscopic major hepatectomy and colectomy for colorectal neoplasm with synchronous liver metastasis: safety, feasibility and short-term outcome[J]. *Surgery*, 2013,

- 153(6):861-865. DOI:10.1016/j.surg.2012.06.007.
- [152] Ratti F, Schadde E, Masetti M, et al. Strategies to increase the resectability of patients with colorectal liver metastases: a multi-center case-match analysis of ALPPS and conventional two-stage hepatectomy[J]. *Ann Surg Oncol*, 2015, 22(6):1933-1942. DOI:10.1245/s10434-014-4291-4.
- [153] Villegas Herrera MT, Becerra Massare A, Muffak Granero K. Liver metastasis from colorectal cancer 12 years after liver transplantation[J]. *Rev Esp Enferm Dig*, 2017, 109(3): 236. DOI:10.17235/reed.2017.4507/2016.
- [154] Tabbal M, Alkhalifa AM, AlQattan AS, et al. Salvage liver transplantation after resection of colorectal cancer liver metastasis with favorable outcomes: a case report and review of the literature[J]. *BMC Gastroenterol*, 2021, 21(1): 191. DOI:10.1186/s12876-021-01778-6.
- [155] Faber W, Seehofer D, Neuhaus P, et al. Repeated liver resection for recurrent hepatocellular carcinoma[J]. *J Gastroenterol Hepatol*, 2011, 26(7): 1189-1194. DOI:10.1111/j.1440-1746.2011.06721.x.
- [156] Adam R, Hoti E, Bredt LC. Evolution of neoadjuvant therapy for extended hepatic metastases—have we reached our (non-resectable) limit? [J]. *J Surg Oncol*, 2010, 102(8):922-931. DOI:10.1002/jso.21727.
- [157] Kanzaki R, Higashiyama M, Oda K, et al. Outcome of surgical resection for recurrent pulmonary metastasis from colorectal carcinoma[J]. *Am J Surg*, 2011, 202(4):419-426. DOI:10.1016/j.amjsurg.2010.08.016.
- [158] Elias D, Benizri E, Pocard M, et al. Treatment of synchronous peritoneal carcinomatosis and liver metastases from colorectal cancer[J]. *Eur J Surg Oncol*, 2006, 32(6):632-636. DOI:10.1016/j.ejso.2006.03.013.
- [159] Carpizo DR, D'Angelica M. Liver resection for metastatic colorectal cancer in the presence of extrahepatic disease [J]. *Lancet Oncol*, 2009, 10(8):801-809. DOI:10.1016/S1470-2045(09)70081-6.
- [160] Cleary JM, Tanabe KT, Lauwers GY, et al. Hepatic toxicities associated with the use of preoperative systemic therapy in patients with metastatic colorectal adenocarcinoma to the liver[J]. *Oncologist*, 2009, 14(11): 1095-1105. DOI: 10.1634/theoncologist.2009-0152.
- [161] Tanaka K, Adam R, Shimada H, et al. Role of neoadjuvant chemotherapy in the treatment of multiple colorectal metastases to the liver[J]. *Br J Surg*, 2003, 90(8): 963-969. DOI: 10.1002/bjs.4160.
- [162] Leonard GD, Brenner B, Kemeny NE. Neoadjuvant chemotherapy before liver resection for patients with unresectable liver metastases from colorectal carcinoma[J]. *J Clin Oncol*, 2005, 23(9):2038-2048. DOI:10.1200/JCO.2005. 00.349.
- [163] Adams RB, Haller DG, Roh MS. Improving resectability of hepatic colorectal metastases: expert consensus statement by Abdalla et al[J]. *Ann Surg Oncol*, 2006, 13(10):1281-1283. DOI:10.1245/s10434-006-9149-y.
- [164] Benoist S, Brouquet A, Penna C, et al. Complete response of colorectal liver metastases after chemotherapy: does it mean cure? [J]. *J Clin Oncol*, 2006, 24(24):3939-3945. DOI: 10.1200/JCO.2006.05.8727.
- [165] Chiappa A, Bertani E, Makuuchi M, et al. Neoadjuvant chemotherapy followed by hepatectomy for primarily resectable colorectal cancer liver metastases[J]. *Hepatogastroenterology*, 2009, 56(91/92):829-834.
- [166] Fujisaki S, Takashina M, Suzuki S, et al. Does complete response of liver metastases from colorectal cancer after chemotherapy mean cure? [J]. *Gan To Kagaku Ryoho*, 2013, 40(12):1662-1664.
- [167] Gruenberger B, Scheithauer W, Punzengruber R, et al. Importance of response to neoadjuvant chemotherapy in potentially curable colorectal cancer liver metastases[J]. *BMC Cancer*, 2008, 8:120. DOI:10.1186/1471-2407-8-120.
- [168] Folprecht G, Grothey A, Alberts S, et al. Neoadjuvant treatment of unresectable colorectal liver metastases: correlation between tumour response and resection rates[J]. *Ann Oncol*, 2005, 16(8):1311-1319. DOI:10.1093/annonc/mdi246.
- [169] Mentha G, Majno P, Terraz S, et al. Treatment strategies for the management of advanced colorectal liver metastases detected synchronously with the primary tumour[J]. *Eur J Surg Oncol*, 2007, 33(Suppl 2):S76-S83. DOI:10.1016/j.ejso.2007.09.016.
- [170] Nordlinger B, Sorbye H, Glimelius B, et al. Perioperative chemotherapy with FOLFOX4 and surgery versus surgery alone for resectable liver metastases from colorectal cancer (EORTC Intergroup trial 40983): a randomised controlled trial[J]. *Lancet*, 2008, 371(9617):1007-1016. DOI:10.1016/S0140-6736(08)60455-9.
- [171] Aloia T, Sebah M, Plasse M, et al. Liver histology and surgical outcomes after preoperative chemotherapy with fluorouracil plus oxaliplatin in colorectal cancer liver metastases[J]. *J Clin Oncol*, 2006, 24(31): 4983-4990. DOI: 10.1200/JCO.2006.05.8156.
- [172] Karoui M, Penna C, Amin-Hashem M, et al. Influence of preoperative chemotherapy on the risk of major hepatectomy for colorectal liver metastases[J]. *Ann Surg*, 2006, 243(1):1-7. DOI:10.1097/01.sla.0000193603.26265.c3.
- [173] Kataoka K, Kanazawa A, Nakajima A, et al. Feasibility and potential benefit of preoperative chemotherapy for colorectal liver metastasis (CLM): a single-centered retrospective study[J]. *Surg Today*, 2013, 43(10):1154-1161. DOI:10.1007/s00595-012-0410-7.
- [174] Malik HZ, Farid S, Al-Mukthar A, et al. A critical appraisal of the role of neoadjuvant chemotherapy for colorectal liver metastases: a case-controlled study[J]. *Ann Surg Oncol*, 2007, 14(12): 3519-3526. DOI: 10.1245/s10434-007-9533-2.
- [175] Straka M, Skrovina M, Soumarova R, et al. Up front hepatectomy for metastatic rectal carcinoma-reversed, liver first approach. Early experience with 15 patients[J]. *Neoplasma*, 2014, 61(4):447-452. DOI:10.4149/neo_2014_055.
- [176] Welsh FK, Tilney HS, Tekkis PP, et al. Safe liver resection following chemotherapy for colorectal metastases is a matter of timing[J]. *Br J Cancer*, 2007, 96(7):1037-1042. DOI:10.1038/sj.bjc.6603670.
- [177] Zhu C, Ren XH, Liu D, et al. Oxaliplatin-induced hepatic sinusoidal obstruction syndrome[J]. *Toxicology*, 2021, 460: 152882. DOI:10.1016/j.tox.2021.152882.
- [178] Fernandez FG, Ritter J, Goodwin JW, et al. Effect of steatohepatitis associated with irinotecan or oxaliplatin pretreatment on resectability of hepatic colorectal metastases[J]. *J Am Coll Surg*, 2005, 200(6): 845-853. DOI: 10.1016/j.jamcollsurg.2005.01.024.
- [179] Pawlik TM, Olino K, Gleisner AL, et al. Preoperative chemo-

- therapy for colorectal liver metastases: impact on hepatic histology and postoperative outcome[J]. *J Gastrointest Surg*, 2007,11(7):860-868. DOI:10.1007/s11605-007-0149-4.
- [180] Vauthey JN, Pawlik TM, Ribero D, et al. Chemotherapy regimen predicts steatohepatitis and an increase in 90-day mortality after surgery for hepatic colorectal metastases[J]. *J Clin Oncol*, 2006,24(13):2065-2072. DOI:10.1200/JCO.2005.05.3074.
- [181] Gomez D, Malik HZ, Bonney GK, et al. Steatosis predicts postoperative morbidity following hepatic resection for colorectal metastasis[J]. *Br J Surg*, 2007,94(11):1395-1402. DOI:10.1002/bjs.5820.
- [182] Nakano H, Oussoultzoglou E, Rosso E, et al. Sinusoidal injury increases morbidity after major hepatectomy in patients with colorectal liver metastases receiving preoperative chemotherapy[J]. *Ann Surg*, 2008,247(1):118-124. DOI:10.1097/SLA.0b013e31815774de.
- [183] Adam R, Wicherts DA, de Haas RJ, et al. Complete pathologic response after preoperative chemotherapy for colorectal liver metastases: myth or reality? [J]. *J Clin Oncol*, 2008,26(10):1635-1641. DOI:10.1200/JCO.2007.13.7471.
- [184] Horgan PG. Surgical management of disappearing colorectal liver metastases (*Br J Surg* 2013;100:1414-1420)[J]. *Br J Surg*, 2013,100(11):1420. DOI:10.1002/bjs.9219.
- [185] van Vledder MG, de Jong MC, Pawlik TM, et al. Disappearing colorectal liver metastases after chemotherapy: should we be concerned? [J]. *J Gastrointest Surg*, 2010, 14(11):1691-1700. DOI:10.1007/s11605-010-1348-y.
- [186] Barimani D, Kauppila JH, Stureson C, et al. Imaging in disappearing colorectal liver metastases and their accuracy: a systematic review[J]. *World J Surg Oncol*, 2020,18(1):264. DOI:10.1186/s12957-020-02037-w.
- [187] Adam R, Delvart V, Pascal G, et al. Rescue surgery for unresectable colorectal liver metastases downstaged by chemotherapy: a model to predict long-term survival[J]. *Ann Surg*, 2004,240(4):644-657. DOI:10.1097/01.sla.0000141198.92114.f6.
- [188] Benoist S, Nordlinger B. Neoadjuvant treatment before resection of liver metastases[J]. *Eur J Surg Oncol*, 2007,33 (Suppl 2):S35-S41. DOI:10.1016/j.ejso.2007.09.022.
- [189] Poultides GA, Servais EL, Saltz LB, et al. Outcome of primary tumor in patients with synchronous stage IV colorectal cancer receiving combination chemotherapy without surgery as initial treatment[J]. *J Clin Oncol*, 2009,27 (20):3379-3384. DOI:10.1200/JCO.2008.20.9817.
- [190] Reddy SK, Barbas AS, Clary BM. Synchronous colorectal liver metastases: is it time to reconsider traditional paradigms of management? [J]. *Ann Surg Oncol*, 2009,16(9):2395-2410. DOI:10.1245/s10434-009-0372-1.
- [191] Coskun U, Buyukberber S, Yaman E, et al. Xelox (capecitabine plus oxaliplatin) as neoadjuvant chemotherapy of unresectable liver metastases in colorectal cancer patients [J]. *Neoplasma*, 2008, 55(1):65-70.
- [192] Gruenberger B, Tamandl D, Schueller J, et al. Bevacizumab, capecitabine, and oxaliplatin as neoadjuvant therapy for patients with potentially curable metastatic colorectal cancer [J]. *J Clin Oncol*, 2008,26(11):1830-1835. DOI:10.1200/JCO.2007.13.7679.
- [193] Mehta NN, Ravikumar R, Coldham CA, et al. Effect of preoperative chemotherapy on liver resection for colorectal liver metastases[J]. *Eur J Surg Oncol*, 2008,34(7):782-786. DOI:10.1016/j.ejso.2007.09.007.
- [194] Parkin E, O'Reilly DA, Adam R, et al. The effect of hepatic steatosis on survival following resection of colorectal liver metastases in patients without preoperative chemotherapy [J]. *HPB (Oxford)*, 2013,15(6):463-472. DOI:10.1111/hpb.12007.
- [195] Clancy TE, Dixon E, Perlis R, et al. Hepatic arterial infusion after curative resection of colorectal cancer metastases: a meta-analysis of prospective clinical trials[J]. *J Gastrointest Surg*, 2005,9(2):198-206. DOI:10.1016/j.gassur.2004.07.004.
- [196] Kemeny N, Eid A, Stockman J, et al. Hepatic arterial infusion of floxuridine and dexamethasone plus high-dose Mitomycin C for patients with unresectable hepatic metastases from colorectal carcinoma[J]. *J Surg Oncol*, 2005,91(2):97-101. DOI:10.1002/jso.20286.
- [197] Kemeny N, Jarnagin W, Paty P, et al. Phase I trial of systemic oxaliplatin combination chemotherapy with hepatic arterial infusion in patients with unresectable liver metastases from colorectal cancer[J]. *J Clin Oncol*, 2005,23(22):4888-4896. DOI:10.1200/JCO.2005.07.100.
- [198] Kishi Y, Zorzi D, Contreras CM, et al. Extended preoperative chemotherapy does not improve pathologic response and increases postoperative liver insufficiency after hepatic resection for colorectal liver metastases[J]. *Ann Surg Oncol*, 2010,17(11):2870-2876. DOI:10.1245/s10434-010-1166-1.
- [199] Benoist S, Nordlinger B. The role of preoperative chemotherapy in patients with resectable colorectal liver metastases[J]. *Ann Surg Oncol*, 2009,16(9):2385-2390. DOI:10.1245/s10434-009-0492-7.
- [200] Choti MA. Chemotherapy-associated hepatotoxicity: do we need to be concerned? [J]. *Ann Surg Oncol*, 2009,16(9):2391-2394. DOI:10.1245/s10434-009-0512-7.
- [201] Samantas E, Derveniz C, Rigatos SK. Adjuvant chemotherapy for colon cancer: evidence on improvement in survival[J]. *Dig Dis*, 2007,25(1):67-75. DOI:10.1159/000099172.
- [202] Adam R, Bhangui P, Poston G, et al. Is perioperative chemotherapy useful for solitary, metachronous, colorectal liver metastases? [J]. *Ann Surg*, 2010,252(5):774-787. DOI:10.1097/SLA.0b013e3181fc3e3.
- [203] Schwarz RE, Berlin JD, Lenz HJ, et al. Systemic cytotoxic and biological therapies of colorectal liver metastases: expert consensus statement[J]. *HPB (Oxford)*, 2013,15(2):106-115. DOI:10.1111/j.1477-2574.2012.00558.x.
- [204] Vadegar HJ. Current therapeutic options for colorectal liver metastases[J]. *Indian J Gastroenterol*, 2007,26(1):26-29.
- [205] De Greef K, Rolfo C, Russo A, et al. Multidisciplinary management of patients with liver metastasis from colorectal cancer[J]. *World J Gastroenterol*, 2016,22(32):7215-7225. DOI:10.3748/wjg.v22.i32.7215.
- [206] Go  r   D, Benhaim L, Bonnet S, et al. Adjuvant chemotherapy after resection of colorectal liver metastases in patients at high risk of hepatic recurrence: a comparative study between hepatic arterial infusion of oxaliplatin and modern systemic chemotherapy[J]. *Ann Surg*, 2013,257(1):114-120. DOI:10.1097/SLA.0b013e31827b9005.
- [207] House MG, Kemeny NE, G  nen M, et al. Comparison of adjuvant systemic chemotherapy with or without hepatic arterial infusional chemotherapy after hepatic resection for

- metastatic colorectal cancer[J]. *Ann Surg*, 2011, 254(6): 851-856. DOI: 10.1097/SLA.0b013e31822f4f88.
- [208] Kemeny NE, Jarnagin WR, Capanu M, et al. Randomized phase II trial of adjuvant hepatic arterial infusion and systemic chemotherapy with or without bevacizumab in patients with resected hepatic metastases from colorectal cancer[J]. *J Clin Oncol*, 2011, 29(7): 884-889. DOI: 10.1200/JCO.2010.32.5977.
- [209] Abdalla EK. Commentary: Radiofrequency ablation for colorectal liver metastases: do not blame the biology when it is the technology[J]. *Am J Surg*, 2009, 197(6): 737-739. DOI: 10.1016/j.amjsurg.2008.06.029.
- [210] Folprecht G, Gruenberger T, Bechstein WO, et al. Tumour response and secondary resectability of colorectal liver metastases following neoadjuvant chemotherapy with cetuximab: the CELIM randomised phase 2 trial[J]. *Lancet Oncol*, 2010, 11(1): 38-47. DOI: 10.1016/S1470-2045(09)70330-4.
- [211] Adam R. Chemotherapy and surgery: new perspectives on the treatment of unresectable liver metastases[J]. *Ann Oncol*, 2003, 14(Suppl 2): ii13-ii16. DOI: 10.1093/annonc/mdg731.
- [212] Goldberg RM, Sargent DJ, Morton RF, et al. Randomized controlled trial of reduced-dose bolus fluorouracil plus leucovorin and irinotecan or infused fluorouracil plus leucovorin and oxaliplatin in patients with previously untreated metastatic colorectal cancer: a North American Inter-group Trial[J]. *J Clin Oncol*, 2006, 24(21): 3347-3353. DOI: 10.1200/JCO.2006.06.1317.
- [213] Cals L, Rixe O, François E, et al. Dose-finding study of weekly 24-h continuous infusion of 5-fluorouracil associated with alternating oxaliplatin or irinotecan in advanced colorectal cancer patients[J]. *Ann Oncol*, 2004, 15(7): 1018-1024. DOI: 10.1093/annonc/mdh259.
- [214] Falcone A, Ricci S, Brunetti I, et al. Phase III trial of infusional fluorouracil, leucovorin, oxaliplatin, and irinotecan (FOLFOXIRI) compared with infusional fluorouracil, leucovorin, and irinotecan (FOLFIRI) as first-line treatment for metastatic colorectal cancer: the Gruppo Oncologico Nord Ovest[J]. *J Clin Oncol*, 2007, 25(13): 1670-1676. DOI: 10.1200/JCO.2006.09.0928.
- [215] Tournigand C, André T, Achille E, et al. FOLFIRI followed by FOLFOX6 or the reverse sequence in advanced colorectal cancer: a randomized GERCOR study[J]. *J Clin Oncol*, 2004, 22(2): 229-237. DOI: 10.1200/JCO.2004.05.113.
- [216] Hochster HS, Hart LL, Ramanathan RK, et al. Safety and efficacy of oxaliplatin and fluoropyrimidine regimens with or without bevacizumab as first-line treatment of metastatic colorectal cancer: results of the TREE Study[J]. *J Clin Oncol*, 2008, 26(21): 3523-3529. DOI: 10.1200/JCO.2007.15.4138.
- [217] Piessevaux H, Buyse M, Schlichting M, et al. Use of early tumor shrinkage to predict long-term outcome in metastatic colorectal cancer treated with cetuximab[J]. *J Clin Oncol*, 2013, 31(30): 3764-3775. DOI: 10.1200/JCO.2012.42.8532.
- [218] Suzuki C, Blomqvist L, Sundin A, et al. The initial change in tumor size predicts response and survival in patients with metastatic colorectal cancer treated with combination chemotherapy[J]. *Ann Oncol*, 2012, 23(4): 948-954. DOI: 10.1093/annonc/mdr350.
- [219] Ye LC, Wei Y, Zhu DX, et al. Impact of early tumor shrinkage on clinical outcome in wild-type-KRAS colorectal liver metastases treated with cetuximab[J]. *J Gastroenterol Hepatol*, 2015, 30(4): 674-679. DOI: 10.1111/jgh.12847.
- [220] Alberts SR, Horvath WL, Sternfeld WC, et al. Oxaliplatin, fluorouracil, and leucovorin for patients with unresectable liver-only metastases from colorectal cancer: a North Central Cancer Treatment Group phase II study[J]. *J Clin Oncol*, 2005, 23(36): 9243-9249. DOI: 10.1200/JCO.2005.07.740.
- [221] Giacchetti S, Itzhaki M, Gruia G, et al. Long-term survival of patients with unresectable colorectal cancer liver metastases following infusional chemotherapy with 5-fluorouracil, leucovorin, oxaliplatin and surgery[J]. *Ann Oncol*, 1999, 10(6): 663-669. DOI: 10.1023/a: 1008347829017.
- [222] Pernot S, Artru P, Mithieux F, et al. Complete pathological response of unresectable liver metastases from colorectal cancer after trans-arterial chemoembolization with drug-eluting beads loaded with irinotecan (DEBIRI) and concomitant systemic FOLFOX: a case report from the FFCD 1201 trial[J]. *Clin Res Hepatol Gastroenterol*, 2015, 39(6): e73-e77. DOI: 10.1016/j.clinre.2015.06.004.
- [223] Tang WT, Ren L, Liu TS, et al. Bevacizumab plus mFOLFOX6 versus mFOLFOX6 alone as first-line treatment for RAS mutant unresectable colorectal liver-limited metastases: the BECOME randomized controlled trial[J]. *J Clin Oncol*, 2020, 38(27): 3175-3184. DOI: 10.1200/JCO.20.00174.
- [224] Ye LC, Liu TS, Ren L, et al. Randomized controlled trial of cetuximab plus chemotherapy for patients with KRAS wild-type unresectable colorectal liver-limited metastases[J]. *J Clin Oncol*, 2013, 31(16): 1931-1938. DOI: 10.1200/JCO.2012.44.8308.
- [225] Hu HB, Wang K, Huang MJ, et al. Modified FOLFOXIRI with or without cetuximab as conversion therapy in patients with RAS/BRAF wild-type unresectable liver metastases colorectal cancer: the FOCULM multicenter phase II trial[J]. *Oncologist*, 2021, 26(1): e90-e98. DOI: 10.1634/theoncologist.2020-0563.
- [226] André T, Shiu KK, Kim TW, et al. Pembrolizumab in microsatellite-instability-high advanced colorectal cancer[J]. *N Engl J Med*, 2020, 383(23): 2207-2218. DOI: 10.1056/NEJMoa2017699.
- [227] Andre T, Amonkar M, Norquist JM, et al. Health-related quality of life in patients with microsatellite instability-high or mismatch repair deficient metastatic colorectal cancer treated with first-line pembrolizumab versus chemotherapy (KEYNOTE-177): an open-label, randomised, phase 3 trial[J]. *Lancet Oncol*, 2021, 22(5): 665-677. DOI: 10.1016/S1470-2045(21)00064-4.
- [228] Karapetis CS, Jonker D, Daneshmand M, et al. PIK3CA, BRAF, and PTEN status and benefit from cetuximab in the treatment of advanced colorectal cancer: results from NCIC CTG/AGITG CO.17[J]. *Clin Cancer Res*, 2014, 20(3): 744-753. DOI: 10.1158/1078-0432.CCR-13-0606.
- [229] Van Cutsem E, Köhne CH, Hitre E, et al. Cetuximab and chemotherapy as initial treatment for metastatic colorectal cancer[J]. *N Engl J Med*, 2009, 360(14): 1408-1417. DOI: 10.1056/NEJMoa0805019.
- [230] Garufi C, Torsello A, Tumolo S, et al. Cetuximab plus chromodulated irinotecan, 5-fluorouracil, leucovorin and oxaliplatin as neoadjuvant chemotherapy in colorectal liver

- metastases: POCHER trial[J]. *Br J Cancer*,2010,103(10): 1542-1547. DOI:10.1038/sj.bjc.6605940.
- [231] Souglakos J, Androulakis N, Syrigos K, et al. FOLFOXIRI (folinic acid, 5-fluorouracil, oxaliplatin and irinotecan) vs FOLFIRI (folinic acid, 5-fluorouracil and irinotecan) as first-line treatment in metastatic colorectal cancer (MCC): a multicentre randomised phase III trial from the Hellenic Oncology Research Group (HORG)[J]. *Br J Cancer*,2006,94(6):798-805. DOI:10.1038/sj.bjc.6603011.
- [232] Cremolini C, Antoniotti C, Rossini D, et al. Upfront FOLFOXIRI plus bevacizumab and reintroduction after progression versus mFOLFOX6 plus bevacizumab followed by FOLFIRI plus bevacizumab in the treatment of patients with metastatic colorectal cancer (TRIBE2): a multicentre, open-label, phase 3, randomised, controlled trial[J]. *Lancet Oncol*,2020,21(4):497-507. DOI:10.1016/S1470-2045(19)30862-9.
- [233] Cremolini C, Loupakis F, Antoniotti C, et al. FOLFOXIRI plus bevacizumab versus FOLFIRI plus bevacizumab as first-line treatment of patients with metastatic colorectal cancer: updated overall survival and molecular subgroup analyses of the open-label, phase 3 TRIBE study[J]. *Lancet Oncol*,2015,16(13):1306-1315. DOI:10.1016/S1470-2045(15)00122-9.
- [234] Stein A, Atanackovic D, Hildebrandt B, et al. Upfront FOLF-
OXIRI+bevacizumab followed by fluoropyrimidin and bevacizumab maintenance in patients with molecularly unselected metastatic colorectal cancer[J]. *Br J Cancer*,2015,113(6):872-877. DOI:10.1038/bjc.2015.299.
- [235] Tomasello G, Petrelli F, Ghidini M, et al. FOLFOXIRI plus bevacizumab as conversion therapy for patients with initially unresectable metastatic colorectal cancer[J]. *JAMA Oncol*,2017,3(7):e170278. DOI:10.1001/jamaoncol.2017.0278.
- [236] Esin E, Yalcin S. Maintenance strategy in metastatic colorectal cancer: a systematic review[J]. *Cancer Treat Rev*,2016,42:82-90. DOI:10.1016/j.ctrv.2015.10.012.
- [237] Goey KKH, Elias SG, van Tinteren H, et al. Maintenance treatment with capecitabine and bevacizumab versus observation in metastatic colorectal cancer: updated results and molecular subgroup analyses of the phase 3 CAIRO3 study [J]. *Ann Oncol*,2017,28(9):2128-2134. DOI: 10.1093/ann onc/mdx322.
- [238] Hegewisch-Becker S, Graeven U, Lerchenmüller CA, et al. Maintenance strategies after first-line oxaliplatin plus fluoropyrimidine plus bevacizumab for patients with metastatic colorectal cancer (AIO 0207): a randomised, non-inferiority, open-label, phase 3 trial[J]. *Lancet Oncol*,2015,16(13):1355-1369. DOI:10.1016/S1470-2045(15)00042-X.
- [239] Simkens LH, van Tinteren H, May A, et al. Maintenance treatment with capecitabine and bevacizumab in metastatic colorectal cancer (CAIRO3): a phase 3 randomised controlled trial of the Dutch Colorectal Cancer Group[J]. *Lancet*,2015,385(9980):1843-1852. DOI:10.1016/S0140-6736(14)62004-3.
- [240] Stein A, Schwenke C, Folprecht G, et al. Effect of application and intensity of bevacizumab-based maintenance after induction chemotherapy with bevacizumab for metastatic colorectal cancer: a meta-analysis[J]. *Clin Colorectal Cancer*,2016,15(2):e29-e39. DOI:10.1016/j.clcc.2015.12.005.
- [241] Sonbol MB, Mountjoy LJ, Firwana B, et al. The role of maintenance strategies in metastatic colorectal cancer: a systematic review and network meta-analysis of randomized clinical trials[J]. *JAMA Oncol*,2020,6(3):e194489. DOI:10.1001/jamaoncol.2019.4489.
- [242] Aparicio T, Ghiringhelli F, Boige V, et al. Bevacizumab maintenance versus No maintenance during chemotherapy-free intervals in metastatic colorectal cancer: a randomized phase III trial (PRODIGE 9)[J]. *J Clin Oncol*,2018,36(7): 674-681. DOI:10.1200/JCO.2017.75.2931.
- [243] Xu RH, Muro K, Morita S, et al. Modified XELIRI (capecitabine plus irinotecan) versus FOLFIRI (leucovorin, fluorouracil, and irinotecan), both either with or without bevacizumab, as second-line therapy for metastatic colorectal cancer (AXEPT): a multicentre, open-label, randomised, non-inferiority, phase 3 trial[J]. *Lancet Oncol*,2018,19(5): 660-671. DOI:10.1016/S1470-2045(18)30140-2.
- [244] Ducreux M, Malka D, Mendiboure J, et al. Sequential versus combination chemotherapy for the treatment of advanced colorectal cancer (FFCD 2000-05): an open-label, randomised, phase 3 trial[J]. *Lancet Oncol*,2011,12(11):1032-1044. DOI:10.1016/S1470-2045(11)70199-1.
- [245] Koopman M, Antonini NF, Douma J, et al. Sequential versus combination chemotherapy with capecitabine, irinotecan, and oxaliplatin in advanced colorectal cancer (CAIRO): a phase III randomised controlled trial[J]. *Lancet*,2007,370(9582):135-142. DOI:10.1016/S0140-6736(07)61086-1.
- [246] Seymour MT, Maughan TS, Ledermann JA, et al. Different strategies of sequential and combination chemotherapy for patients with poor prognosis advanced colorectal cancer (MRC FOCUS): a randomised controlled trial[J]. *Lancet*,2007,370(9582):143-152. DOI:10.1016/S0140-6736(07)61087-3.
- [247] Grothey A, Van Cutsem E, Sobrero A, et al. Regorafenib monotherapy for previously treated metastatic colorectal cancer (CORRECT): an international, multicentre, randomised, placebo-controlled, phase 3 trial[J]. *Lancet*,2013,381(9863):303-312. DOI:10.1016/S0140-6736(12)61900-X.
- [248] Li J, Qin S, Xu RH, et al. Effect of fruquintinib vs placebo on overall survival in patients with previously treated metastatic colorectal cancer: the FRESCO randomized clinical trial[J]. *JAMA*,2018,319(24):2486-2496. DOI:10.1001/jama.2018.7855.
- [249] Bennisouna J, Borg C, Delord JP, et al. Bevacizumab combined with chemotherapy in the second-line treatment of metastatic colorectal cancer: results from the phase II BEVACOLOR study[J]. *Clin Colorectal Cancer*,2012,11(1): 38-44. DOI:10.1016/j.clcc.2011.05.002.
- [250] Iwamoto S, Hazama S, Kato T, et al. Multicenter phase II study of second-line cetuximab plus folinic acid/5-fluorouracil/irinotecan (FOLFIRI) in KRAS wild-type metastatic colorectal cancer: the FLIER study[J]. *Anticancer Res*,2014,34(4):1967-1973.
- [251] Mayer RJ, Van Cutsem E, Falcone A, et al. Randomized trial of TAS-102 for refractory metastatic colorectal cancer[J]. *N Engl J Med*,2015,372(20):1909-1919. DOI:10.1056/NEJMoa1414325.
- [252] Shitara K, Doi T, Dvorkin M, et al. Trifluridine/tipiracil versus placebo in patients with heavily pretreated metastatic gastric cancer (TAGS): a randomised, double-blind, placebo-controlled, phase 3 trial[J]. *Lancet Oncol*,2018,19(11):1437-

1448. DOI:10.1016/S1470-2045(18)30739-3.
- [253] Hurwitz H, Fehrenbacher L, Novotny W, et al. Bevacizumab plus irinotecan, fluorouracil, and leucovorin for metastatic colorectal cancer[J]. *N Engl J Med*, 2004, 350(23):2335-2342. DOI:10.1056/NEJMoa032691.
- [254] Le DT, Uram JN, Wang H, et al. PD-1 blockade in tumors with mismatch-repair deficiency[J]. *N Engl J Med*, 2015, 372(26):2509-2520. DOI:10.1056/NEJMoa1500596.
- [255] Marabelle A, Le DT, Ascierto PA, et al. Efficacy of pembrolizumab in patients with noncolorectal high microsatellite instability/mismatch repair-deficient cancer: results from the phase II KEYNOTE-158 study[J]. *J Clin Oncol*, 2020, 38(1):1-10. DOI:10.1200/JCO.19.02105.
- [256] Lenz HJ, Van Cutsem E, Luisa Limon M, et al. First-line nivolumab plus low-dose ipilimumab for microsatellite instability-high/mismatch repair-deficient metastatic colorectal cancer: the phase II CheckMate 142 study[J]. *J Clin Oncol*, 2022, 40(2):161-170. DOI:10.1200/JCO.21.01015.
- [257] Le DT, Kim TW, Van Cutsem E, et al. Phase II open-label study of pembrolizumab in treatment-refractory, microsatellite instability-high/mismatch repair-deficient metastatic colorectal cancer: keynote-164[J]. *J Clin Oncol*, 2020, 38(1):11-19. DOI:10.1200/JCO.19.02107.
- [258] Jin Z, Sinicrope FA. Advances in the therapy of BRAF^{V600E} metastatic colorectal cancer[J]. *Expert Rev Anticancer Ther*, 2019, 19(9):823-829. DOI: 10.1080/14737140.2019.1661778.
- [259] Prahallad A, Sun C, Huang SD, et al. Unresponsiveness of colon cancer to BRAF(V600E) inhibition through feedback activation of EGFR[J]. *Nature*, 2012, 483(7387):100-103. DOI:10.1038/nature10868.
- [260] Tabernero J, Grothey A, Van Cutsem E, et al. Encorafenib plus cetuximab as a new standard of care for previously treated BRAF V600E-mutant metastatic colorectal cancer: updated survival results and subgroup analyses from the BEACON study[J]. *J Clin Oncol*, 2021, 39(4):273-284. DOI: 10.1200/JCO.20.02088.
- [261] Kopetz S, Guthrie KA, Morris VK, et al. Randomized trial of irinotecan and cetuximab with or without vemurafenib in BRAF-mutant metastatic colorectal cancer (SWOG S1406) [J]. *J Clin Oncol*, 2021, 39(4):285-294. DOI:10.1200/JCO.20.01994.
- [262] Meric-Bernstam F, Hurwitz H, Raghav KPS, et al. Pertuzumab plus trastuzumab for HER2-amplified metastatic colorectal cancer (MyPathway): an updated report from a multicentre, open-label, phase 2a, multiple basket study[J]. *Lancet Oncol*, 2019, 20(4):518-530. DOI: 10.1016/S1470-2045(18)30904-5.
- [263] Sartore-Bianchi A, Trusolino L, Martino C, et al. Dual-targeted therapy with trastuzumab and lapatinib in treatment-refractory, KRAS codon 12/13 wild-type, HER2-positive metastatic colorectal cancer (HERACLES): a proof-of-concept, multicentre, open-label, phase 2 trial[J]. *Lancet Oncol*, 2016, 17(6):738-746. DOI:10.1016/S1470-2045(16)00150-9.
- [264] Siena S, Di Bartolomeo M, Raghav K, et al. Trastuzumab deruxtecan (DS-8201) in patients with HER2-expressing metastatic colorectal cancer (DESTINY-CRC01): a multicentre, open-label, phase 2 trial[J]. *Lancet Oncol*, 2021, 22(6):779-789. DOI:10.1016/S1470-2045(21)00086-3.
- [265] Chan DL, Alzahrani NA, Morris DL, et al. Systematic review and meta-analysis of hepatic arterial infusion chemotherapy as bridging therapy for colorectal liver metastases[J]. *Surg Oncol*, 2015, 24(3):162-171. DOI:10.1016/j.suronc.2015.06.014.
- [266] D'Angelica MI, Correa-Gallego C, Paty PB, et al. Phase II trial of hepatic artery infusional and systemic chemotherapy for patients with unresectable hepatic metastases from colorectal cancer: conversion to resection and long-term outcomes[J]. *Ann Surg*, 2015, 261(2):353-360. DOI: 10.1097/SLA.0000000000000614.
- [267] McAuliffe JC, Qadan M, D'Angelica MI. Hepatic resection, hepatic arterial infusion pump therapy, and genetic biomarkers in the management of hepatic metastases from colorectal cancer[J]. *J Gastrointest Oncol*, 2015, 6(6):699-708. DOI:10.3978/j.issn.2078-6891.2015.081.
- [268] Levy J, Zuckerman J, Garfinkle R, et al. Intra-arterial therapies for unresectable and chemorefractory colorectal cancer liver metastases: a systematic review and meta-analysis[J]. *HPB (Oxford)*, 2018, 20(10):905-915. DOI:10.1016/j.hpb.2018.04.001.
- [269] Minocha J, Salem R, Lewandowski RJ. Transarterial chemoembolization and yttrium-90 for liver cancer and other lesions[J]. *Clin Liver Dis*, 2014, 18(4):877-890. DOI:10.1016/j.cld.2014.07.007.
- [270] Ammori JB, Kemeny NE, Fong Y, et al. Conversion to complete resection and/or ablation using hepatic artery infusional chemotherapy in patients with unresectable liver metastases from colorectal cancer: a decade of experience at a single institution[J]. *Ann Surg Oncol*, 2013, 20(9):2901-2907. DOI:10.1245/s10434-013-3009-3.
- [271] Mocellin S, Pasquali S, Nitti D. Fluoropyrimidine-HAI (hepatic arterial infusion) versus systemic chemotherapy (SCT) for unresectable liver metastases from colorectal cancer [J]. *Cochrane Database Syst Rev*, 2009(3):CD007823. DOI: 10.1002/14651858.CD007823.pub2.
- [272] Feliberti EC, Wagman LD. Radiofrequency ablation of liver metastases from colorectal carcinoma[J]. *Cancer Control*, 2006, 13(1):48-51. DOI:10.1177/107327480601300107.
- [273] Hammill CW, Billingsley KG, Cassera MA, et al. Outcome after laparoscopic radiofrequency ablation of technically resectable colorectal liver metastases[J]. *Ann Surg Oncol*, 2011, 18(7):1947-1954. DOI:10.1245/s10434-010-1535-9.
- [274] Livraghi T, Solbiati L, Meloni MF, et al. Treatment of focal liver tumors with percutaneous radio-frequency ablation: complications encountered in a multicenter study[J]. *Radiology*, 2003, 226(2):441-451. DOI:10.1148/radiol.2262012198.
- [275] Berber E, Tsinberg M, Tellioglu G, et al. Resection versus laparoscopic radiofrequency thermal ablation of solitary colorectal liver metastasis[J]. *J Gastrointest Surg*, 2008, 12(11):1967-1972. DOI:10.1007/s11605-008-0622-8.
- [276] Brouquet A, Andreou A, Vauthey JN. The management of solitary colorectal liver metastases[J]. *Surgeon*, 2011, 9(5):265-272. DOI:10.1016/j.surge.2010.12.005.
- [277] Knudsen AR, Kannerup AS, Mortensen FV, et al. Radiofrequency ablation of colorectal liver metastases downstaged by chemotherapy[J]. *Acta Radiol*, 2009, 50(7):716-721. DOI: 10.1080/02841850902991634.
- [278] Siperstein AE, Berber E, Ballem N, et al. Survival after radio-

- frequency ablation of colorectal liver metastases: 10-year experience[J]. *Ann Surg*, 2007, 246(4):559-567. DOI:10.1097/SLA.0b013e318155a7b6.
- [279] Rhim H, Lim HK, Kim YS, et al. Radiofrequency ablation of hepatic tumors: lessons learned from 3000 procedures[J]. *J Gastroenterol Hepatol*, 2008, 23(10):1492-1500. DOI:10.1111/j.1440-1746.2008.05550.x.
- [280] Facciorusso A, Di Maso M, Muscatiello N. Microwave ablation versus radiofrequency ablation for the treatment of hepatocellular carcinoma: a systematic review and meta-analysis[J]. *Int J Hyperthermia*, 2016, 32(3):339-344. DOI:10.3109/02656736.2015.1127434.
- [281] Xu ZT, Xie HY, Zhou L, et al. The combination strategy of transarterial chemoembolization and radiofrequency ablation or microwave ablation against hepatocellular carcinoma[J]. *Anal Cell Pathol (Amst)*, 2019, 2019:8619096. DOI:10.1155/2019/8619096.
- [282] Zhang X, Zhou L, Chen B, et al. Microwave ablation with cooled-TIP electrode for liver cancer: an analysis of 160 cases[J]. *Minim Invasive Ther Allied Technol*, 2008, 17(5):303-307. DOI:10.1080/13645700802383926.
- [283] Grundmann RT, Hermanek P, Merkel S, et al. Diagnosis and treatment of colorectal liver metastases-workflow[J]. *Zentralbl Chir*, 2008, 133(3):267-284. DOI:10.1055/s-2008-1076796.
- [284] Shono Y, Tabuse K, Tsuji T, et al. Microwave coagulation therapy for unresectable colorectal metastatic liver tumor [J]. *Gan To Kagaku Ryoho*, 2002, 29(6):856-859.
- [285] De Cobelli F, Calandri M, Della Corte A, et al. Multi-institutional analysis of outcomes for thermosphere microwave ablation treatment of colorectal liver metastases: the SMAC study[J]. *Eur Radiol*, 2022, 32(6):4147-4159. DOI:10.1007/s00330-021-08497-2.
- [286] Chen YY, Perera DS, Yan TD, et al. Applying Fong's CRS liver score in patients with colorectal liver metastases treated by cryotherapy[J]. *Asian J Surg*, 2006, 29(4):238-241. DOI:10.1016/S1015-9584(09)60095-6.
- [287] Seifert JK, Junginger T. Prognostic factors for cryotherapy of colorectal liver metastases[J]. *Eur J Surg Oncol*, 2004, 30(1):34-40. DOI:10.1016/j.ejso.2003.10.009.
- [288] Seifert JK, Junginger T. Cryotherapy for liver tumors: current status, perspectives, clinical results, and review of literature[J]. *Technol Cancer Res Treat*, 2004, 3(2):151-163. DOI:10.1177/153303460400300208.
- [289] Gignoux BM, Ducerf C, Mabrut JY, et al. Cryosurgery of primary and metastatic cancers of the liver[J]. *Ann Chir*, 2001, 126(10):950-959. DOI:10.1016/S0003-3944(01)00637-x.
- [290] Goodman KA, Wiegner EA, Maturen KE, et al. Dose-escalation study of single-fraction stereotactic body radiotherapy for liver malignancies[J]. *Int J Radiat Oncol Biol Phys*, 2010, 78(2):486-493. DOI:10.1016/j.ijrobp.2009.08.020.
- [291] Katz AW, Carey-Sampson M, Muhs AG, et al. Hypofractionated stereotactic body radiation therapy (SBRT) for limited hepatic metastases[J]. *Int J Radiat Oncol Biol Phys*, 2007, 67(3):793-798. DOI:10.1016/j.ijrobp.2006.10.025.
- [292] Schefter TE, Kavanagh BD, Timmerman RD, et al. A phase I trial of stereotactic body radiation therapy (SBRT) for liver metastases[J]. *Int J Radiat Oncol Biol Phys*, 2005, 62(5):1371-1378. DOI:10.1016/j.ijrobp.2005.01.002.
- [293] Mulcahy MF, Mahvash A, Pracht M, et al. Radioembolization with chemotherapy for colorectal liver metastases: a randomized, open-label, international, multicenter, phase III trial[J]. *J Clin Oncol*, 2021, 39(35):3897-3907. DOI:10.1200/JCO.21.01839.
- [294] Wolpin BM, Mayer RJ. Systemic treatment of colorectal cancer[J]. *Gastroenterology*, 2008, 134(5):1296-1310. DOI:10.1053/j.gastro.2008.02.098.
- [295] Grothey A, Sugrue MM, Purdie DM, et al. Bevacizumab beyond first progression is associated with prolonged overall survival in metastatic colorectal cancer: results from a large observational cohort study (BRiTE) [J]. *J Clin Oncol*, 2008, 26(33):5326-5334. DOI:10.1200/JCO.2008.16.3212.
- [296] Welch S, Spithoff K, Rumble RB, et al. Bevacizumab combined with chemotherapy for patients with advanced colorectal cancer: a systematic review[J]. *Ann Oncol*, 2010, 21(6):1152-1162. DOI:10.1093/annonc/mdp533.
- [297] Tol J, Koopman M, Cats A, et al. Chemotherapy, bevacizumab, and cetuximab in metastatic colorectal cancer[J]. *N Engl J Med*, 2009, 360(6):563-572. DOI:10.1056/NEJMoa0808268.
- [298] Hecht JR, Mitchell E, Chidiac T, et al. A randomized phase IIIb trial of chemotherapy, bevacizumab, and panitumumab compared with chemotherapy and bevacizumab alone for metastatic colorectal cancer[J]. *J Clin Oncol*, 2009, 27(5):672-680. DOI:10.1200/JCO.2008.19.8135.
- [299] Spigel DR, Greco FA, Waterhouse D, et al. Phase II trial of FOLFOX6, bevacizumab, and cetuximab in the first-line treatment of metastatic colorectal cancer[J]. *Clin Adv Hematol Oncol*, 2010, 8(7):480-485, 498.
- [300] Sato Y, Matsusaka S, Suenaga M, et al. Cetuximab could be more effective without prior bevacizumab treatment in metastatic colorectal cancer patients[J]. *Onco Targets Ther*, 2015, 8:3329-3336. DOI:10.2147/OTT.S89241.
- [301] Bokemeyer C, Bondarenko I, Makhson A, et al. Fluorouracil, leucovorin, and oxaliplatin with and without cetuximab in the first-line treatment of metastatic colorectal cancer[J]. *J Clin Oncol*, 2009, 27(5):663-671. DOI:10.1200/JCO.2008.20.8397.
- [302] Wong R, Cunningham D, Barbachano Y, et al. A multicentre study of capecitabine, oxaliplatin plus bevacizumab as perioperative treatment of patients with poor-risk colorectal liver-only metastases not selected for upfront resection[J]. *Ann Oncol*, 2011, 22(9):2042-2048. DOI:10.1093/annonc/mdq714.
- [303] Raoul JL, Van Laethem JL, Peeters M, et al. Cetuximab in combination with irinotecan/5-fluorouracil/folinic acid (FOLFIRI) in the initial treatment of metastatic colorectal cancer: a multicentre two-part phase I/II study[J]. *BMC Cancer*, 2009, 9:112. DOI:10.1186/1471-2407-9-112.
- [304] Van Cutsem E, Köhne CH, Láng I, et al. Cetuximab plus irinotecan, fluorouracil, and leucovorin as first-line treatment for metastatic colorectal cancer: updated analysis of overall survival according to tumor KRAS and BRAF mutation status[J]. *J Clin Oncol*, 2011, 29(15):2011-2019. DOI:10.1200/JCO.2010.33.5091.
- [305] Pietrantonio F, Cremolini C, Petrelli F, et al. First-line anti-EGFR monoclonal antibodies in panRAS wild-type metastatic colorectal cancer: a systematic review and meta-analysis[J]. *Crit Rev Oncol Hematol*, 2015, 96(1):156-166. DOI:10.1016/j.critrevonc.2015.05.016.

- [306] De Roock W, Piessevaux H, De Schutter J, et al. KRAS wild-type state predicts survival and is associated to early radiological response in metastatic colorectal cancer treated with cetuximab[J]. *Ann Oncol*, 2008, 19(3):508-515. DOI: 10.1093/annonc/mdm496.
- [307] Karapetis CS, Khambata-Ford S, Jonker DJ, et al. K-ras mutations and benefit from cetuximab in advanced colorectal cancer[J]. *N Engl J Med*, 2008, 359(17):1757-1765. DOI: 10.1056/NEJMoa0804385.
- [308] Amado RG, Wolf M, Peeters M, et al. Wild-type KRAS is required for panitumumab efficacy in patients with metastatic colorectal cancer[J]. *J Clin Oncol*, 2008, 26(10):1626-1634. DOI:10.1200/JCO.2007.14.7116.
- [309] Roth AD, Tejpar S, Delorenzi M, et al. Prognostic role of KRAS and BRAF in stage II and III resected colon cancer: results of the translational study on the PETACC-3, EORTC 40993, SAKK 60-00 trial[J]. *J Clin Oncol*, 2010, 28(3):466-474. DOI:10.1200/JCO.2009.23.3452.
- [310] Price TJ, Hardingham JE, Lee CK, et al. Impact of KRAS and BRAF gene mutation status on outcomes from the phase III AGITG MAX trial of capecitabine alone or in combination with bevacizumab and mitomycin in advanced colorectal cancer[J]. *J Clin Oncol*, 2011, 29(19):2675-2682. DOI:10.1200/JCO.2010.34.5520.
- [311] Saridaki Z, Papadatos-Pastos D, Tzardi M, et al. BRAF mutations, microsatellite instability status and cyclin D1 expression predict metastatic colorectal patients' outcome[J]. *Br J Cancer*, 2010, 102(12):1762-1768. DOI:10.1038/sj.bjc.6605694.
- [312] Maughan TS, Adams RA, Smith CG, et al. Addition of cetuximab to oxaliplatin-based first-line combination chemotherapy for treatment of advanced colorectal cancer: results of the randomised phase 3 MRC COIN trial[J]. *Lancet*, 2011, 377(9783):2103-2114. DOI:10.1016/S0140-6736(11)60613-2.
- [313] Douillard JY, Siena S, Cassidy J, et al. Randomized, phase III trial of panitumumab with infusional fluorouracil, leucovorin, and oxaliplatin (FOLFOX4) versus FOLFOX4 alone as first-line treatment in patients with previously untreated metastatic colorectal cancer: the PRIME study[J]. *J Clin Oncol*, 2010, 28(31):4697-4705. DOI:10.1200/JCO.2009.27.4860.
- [314] McCormack L, Petrowsky H, Jochum W, et al. Hepatic steatosis is a risk factor for postoperative complications after major hepatectomy: a matched case-control study[J]. *Ann Surg*, 2007, 245(6):923-930. DOI:10.1097/01.sla.0000251747.80025.b7.
- [315] Van Cutsem E, Rivera F, Berry S, et al. Safety and efficacy of first-line bevacizumab with FOLFOX, XELOX, FOLFIRI and fluoropyrimidines in metastatic colorectal cancer: the BEAT study[J]. *Ann Oncol*, 2009, 20(11):1842-1847. DOI:10.1093/annonc/mdp233.
- [316] López R, Salgado M, Reboredo M, et al. A retrospective observational study on the safety and efficacy of first-line treatment with bevacizumab combined with FOLFIRI in metastatic colorectal cancer[J]. *Br J Cancer*, 2010, 103(10):1536-1541. DOI:10.1038/sj.bjc.6605938.
- [317] Chaudhury P, Hassanain M, Bouganim N, et al. Perioperative chemotherapy with bevacizumab and liver resection for colorectal cancer liver metastasis[J]. *HPB (Oxford)*, 2010, 12(1):37-42. DOI:10.1111/j.1477-2574.2009.00119.x.
- [318] Cartwright TH, Yim YM, Yu E, et al. Survival outcomes of bevacizumab beyond progression in metastatic colorectal cancer patients treated in US community oncology[J]. *Clin Colorectal Cancer*, 2012, 11(4):238-246. DOI:10.1016/j.clcc.2012.05.005.
- [319] Hamamoto Y, Yamaguchi T, Nishina T, et al. A phase I/II study of XELIRI plus bevacizumab as second-line chemotherapy for Japanese patients with metastatic colorectal cancer (BIX study)[J]. *Oncologist*, 2014, 19(11):1131-1132. DOI:10.1634/theoncologist.2014-0159.
- [320] Masi G, Salvatore L, Boni L, et al. Continuation or reintroduction of bevacizumab beyond progression to first-line therapy in metastatic colorectal cancer: final results of the randomized BEBYP trial[J]. *Ann Oncol*, 2015, 26(4):724-730. DOI:10.1093/annonc/mdv012.
- [321] Bennouna J, Phelip JM, André T, et al. Observational cohort study of patients with metastatic colorectal cancer initiating chemotherapy in combination with bevacizumab (CONCERT)[J]. *Clin Colorectal Cancer*, 2017, 16(2):129-140. DOI:10.1016/j.clcc.2016.07.013.
- [322] Yin C, Ma G, Rong Y, et al. The efficacy of bevacizumab in different line chemotherapy for Chinese patients with metastatic colorectal cancer[J]. *J Cancer*, 2016, 7(13):1901-1906. DOI:10.7150/jca.15802.
- [323] D'Angelica M, Kornprat P, Gonen M, et al. Lack of evidence for increased operative morbidity after hepatectomy with perioperative use of bevacizumab: a matched case-control study[J]. *Ann Surg Oncol*, 2007, 14(2):759-765. DOI:10.1245/s10434-006-9074-0.
- [324] Reddy SK, Morse MA, Hurwitz HI, et al. Addition of bevacizumab to irinotecan-and oxaliplatin-based preoperative chemotherapy regimens does not increase morbidity after resection of colorectal liver metastases[J]. *J Am Coll Surg*, 2008, 206(1):96-106. DOI:10.1016/j.jamcollsurg.2007.06.290.
- [325] Starlinger P, Alidzanovic L, Schauer D, et al. Neoadjuvant bevacizumab persistently inactivates VEGF at the time of surgery despite preoperative cessation[J]. *Br J Cancer*, 2012, 107(6):961-966. DOI:10.1038/bjc.2012.342.
- [326] Shitara K, Yamanaka T, Denda T, et al. REVERCE: a randomized phase II study of regorafenib followed by cetuximab versus the reverse sequence for previously treated metastatic colorectal cancer patients[J]. *Ann Oncol*, 2019, 30(2):259-265. DOI:10.1093/annonc/mdy526.
- [327] Li J, Qin SK, Xu RH, et al. Regorafenib plus best supportive care versus placebo plus best supportive care in Asian patients with previously treated metastatic colorectal cancer (CONCUR): a randomised, double-blind, placebo-controlled, phase 3 trial[J]. *Lancet Oncol*, 2015, 16(6):619-629. DOI:10.1016/S1470-2045(15)70156-7.